

THE PRESENT AND FUTURE

STATE-OF-THE-ART REVIEW

Anomalous Aortic Origin of a Coronary Artery From the Inappropriate Sinus of Valsalva



Michael K. Cheezum, MD,^{a,b} Richard R. Liberthson, MD,^c Nishant R. Shah, MD, MPH, MSc,^d Todd C. Villines, MD,^e Patrick T. O’Gara, MD,^a Michael J. Landzberg, MD,^f Ron Blankstein, MD^a

ABSTRACT

Anomalous aortic origin of a coronary artery (AAOCA) from the inappropriate sinus of Valsalva is increasingly recognized by cardiac imaging. Although most AAOCA subtypes are benign, autopsy studies report an associated risk of sudden death with interarterial anomalous left coronary artery (ALCA) and anomalous right coronary artery (ARCA). Despite efforts to identify high-risk ALCA and ARCA patients who may benefit from surgical repair, debate remains regarding their classification, prevalence, risk stratification, and management. We comprehensively reviewed 77 studies reporting the prevalence of AAOCA among >1 million patients, and 20 studies examining outcomes of interarterial ALCA/ARCA patients. Observational data suggests that interarterial ALCA is rare (weighted prevalence = 0.03%; 95% confidence interval [CI]: 0.01% to 0.04%) compared with interarterial ARCA (weighted prevalence = 0.23%; 95% CI: 0.17% to 0.31%). Recognizing the challenges in managing these patients, we review cardiac tests used to examine AAOCA and knowledge gaps in management. (*J Am Coll Cardiol* 2017;69:1592–608) Published by Elsevier on behalf of the American College of Cardiology Foundation.

Congenital coronary artery anomalies (CAA) are rare and may be broadly classified as abnormalities of coronary artery origin, course, destination, and size or number of vessels (1,2). This review focuses on anomalous aortic origin of a coronary artery (AAOCA) arising at or above the inappropriate sinus of Valsalva. Although classification of these cases varies (1–4), AAOCA arise from the aorta by a separate ostium, shared or common ostium, or as a branch vessel (5). Among subtypes, our discussion will focus on anomalous left coronary artery (ALCA) arising at or above the right sinus of Valsalva

and anomalous right coronary artery (ARCA) arising at or above the left sinus of Valsalva. Rarely, AAOCA vessels may also arise from the “noncoronary” sinus. AAOCA are further characterized by 1 of 5 course subtypes as interarterial, subpulmonic (intraconal or intraseptal), pre-pulmonic, retroaortic, or retrocardiac (Central Illustration). Additionally, AAOCA may have an early intramural segment (within the aortic wall), as seen in the majority of interarterial cases. Among course subtypes, the potential for sudden cardiac death (SCD) has been largely attributed to an interarterial course between the aorta and pulmonary



Listen to this manuscript’s audio summary by JACC Editor-in-Chief Dr. Valentin Fuster.



From the ^aDepartments of Medicine and Radiology, Cardiovascular Division, Brigham and Women’s Hospital, Harvard Medical School, Boston, Massachusetts; ^bDepartment of Medicine, Cardiology Service, Fort Belvoir Community Hospital, Ft. Belvoir, Virginia; ^cDepartment of Medicine, Division of Cardiology, Massachusetts General Hospital, Harvard Medical School, Boston, Massachusetts; ^dLifespan Cardiovascular Institute, Division of Cardiovascular Medicine, Department of Medicine, Brown University Alpert School of Medicine, Providence, Rhode Island; ^eDepartment of Medicine, Cardiology Service, Walter Reed National Military Medical Center, Bethesda Maryland; and the ^fDepartment of Cardiology, Boston Children’s Hospital, Boston, Massachusetts. The opinions and assertions herein are those of the authors alone, and do not represent the views of the U.S. Army, Office of the Surgeon General, Department of Defense, or the U.S. Government. The authors have reported that they have no relationships relevant to the contents of this paper to disclose.

Manuscript received October 7, 2016; revised manuscript received December 5, 2016, accepted January 3, 2017.

artery (**Figure 1A**) (6). By comparison, a subpulmonic course exits the aorta below the pulmonic valve and traverses the right ventricular outflow tract, pulmonary infundibulum, and interventricular septum (**Figure 1B**) (7). Although prior studies with invasive angiography and echocardiography provide limited visualization of these course subtypes, coronary computed tomography angiography (CTA), magnetic resonance angiography (MRA), and intravascular ultrasound (IVUS) are improving characterization of AAOCA vessels.

Although evidence demonstrates that interarterial ALCA and ARCA may be associated with an increased risk of SCD among AAOCA subtypes (6), the prevalence of AAOCA and their associated absolute risk of SCD in the general population is unknown. Thus, controversy remains regarding the optimal approach to risk stratify and manage these patients. With increasing recognition of AAOCA, we aimed to review the following: 1) the observed prevalence of AAOCA arising at or above the inappropriate sinus of Valsalva with attention to the interarterial course subtype; 2) the use of cardiac testing to examine AAOCA; 3) outcomes of interarterial ALCA and ARCA patients; and 4) recommendations and knowledge gaps in current management.

OBSERVED PREVALENCE OF AAOCA IN CLINICAL PRACTICE

We performed a comprehensive review of published reports to examine the observed prevalence of AAOCA arising at or above the inappropriate sinus of Valsalva on cardiac testing with the course subtypes shown in the **Central Illustration**. Studies were included if they examined patients by invasive coronary angiography (ICA), transthoracic echocardiography (TTE), coronary CTA, or MRA. Detailed methods, and inclusion and exclusion criteria are described in **Online Appendix A**, incorporating evidence from 77 studies and >1 million patients undergoing cardiac testing (**Online Figure 1**).

In **Figure 2**, we summarize the observed prevalence of AAOCA arising at or above the inappropriate sinus of Valsalva as the combined rate of all course subtypes (interarterial, subpulmonic, pre-pulmonic, retroaortic, and retrocardiac) across included studies. As shown, there is significant variability in the observed prevalence of AAOCA, which may be attributed to inherent referral bias, differences in age groups and presentation of various cohorts, variable inclusion criteria and AAOCA course descriptions, and limitations in the ability of each modality to examine AAOCA. To date, few studies have screened patients

for AAOCA in the absence of a clinical indication for testing (**Online Appendix A, Online Table 1**) (8-12). Consequently, the true prevalence of AAOCA in the general population remains unknown.

In **Figure 3**, we focus specifically on the observed rate of interarterial ARCA and interarterial ALCA cases among included studies. As shown, the frequency of interarterial ALCA is rare (weighted prevalence = 0.03%; 95% confidence interval [CI]: 0.01% to 0.04%) by comparison with interarterial ARCA (0.23%; 95% CI: 0.17% to 0.31%). The observed prevalence of the remaining course subtypes is listed in **Online Table 2**, with a retroaortic course comprising the most common subtype (prevalence = 0.28%; 95% CI: 0.21% to 0.35%).

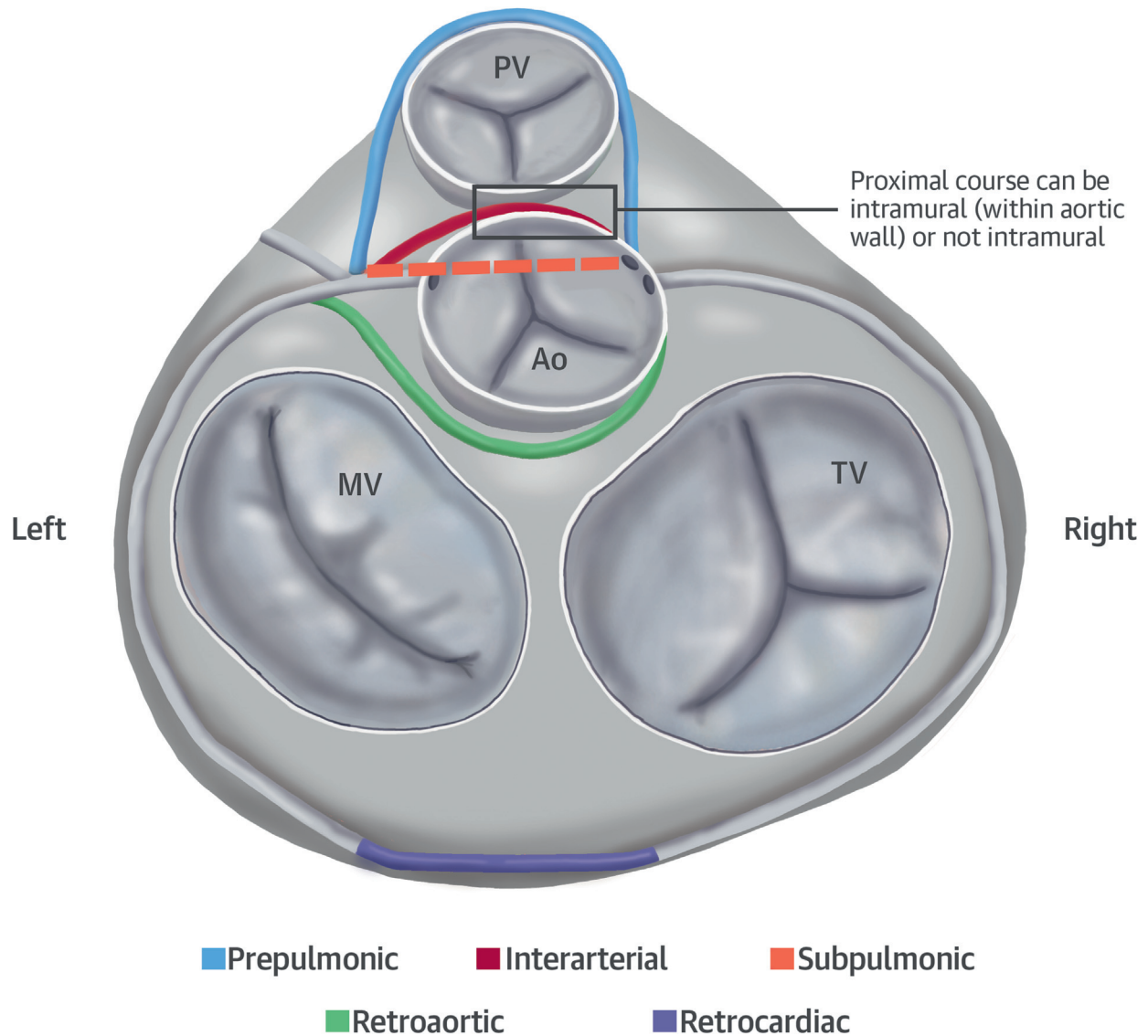
EVALUATION OF AAOCA

TRANSTHORACIC AND TRANSESOPHAGEAL ECHOCARDIOGRAPHY. TTE is a common technique used to evaluate young patients with suspected or known cardiac disease, as a noninvasive, rapid, and widely available test with low cost (**Figure 4**). Yet TTE has limited accuracy to detect AAOCA, requiring experienced operators to identify coronary ostia. In a study by Thankavel et al. (13), a standardized TTE protocol improved AAOCA detection from 0.02% to 0.22% of patients. TTE also depends on patient habitus for optimal image quality. Across studies designed to visualize AAOCA, 6% to 10% of patients were excluded on the basis of an uninterpretable TTE (8,9). Even after excluding unsatisfactory cases, Pelliccia et al. (8) were unable to visualize the RCA ostium in 20% of young athletes, a population expected to have good image quality. Lastly, TTE has limited spatial resolution and lacks detailed characterization of AAOCA features and surrounding structures (14). Among 159 AAOCA patients in the CHSS (Congenital Heart Surgeon's Society) registry, there was limited agreement (weighted kappa) between institutional and expert TTE reports and surgical findings of AAOCA measures (i.e., interarterial course, intramural course, and acute angle takeoff) (15).

Transesophageal echocardiography has been used to identify AAOCA (15-23) and may be useful to visualize CAA perioperatively (24). With the addition of 3-dimensional transesophageal echocardiography, visualization of AAOCA and their relation to surrounding anatomy may improve (25). At this time, however, transesophageal echocardiography is not a

ABBREVIATIONS AND ACRONYMS

- AAOCA** = anomalous aortic origin of a coronary artery
- ALCA** = anomalous left coronary artery
- ANOCOR** = anomalous connections of coronary arteries
- ARCA** = anomalous right coronary artery
- CAA** = coronary artery anomaly
- CI** = confidence interval
- CTA** = computed tomography angiography
- FFR** = fractional flow reserve
- ICA** = invasive coronary angiography
- IVUS** = intravascular ultrasound
- MRA** = magnetic resonance angiography
- PCI** = percutaneous coronary intervention
- SCD** = sudden cardiac death
- TTE** = transthoracic echocardiography

CENTRAL ILLUSTRATION AAOCA: Course Subtypes

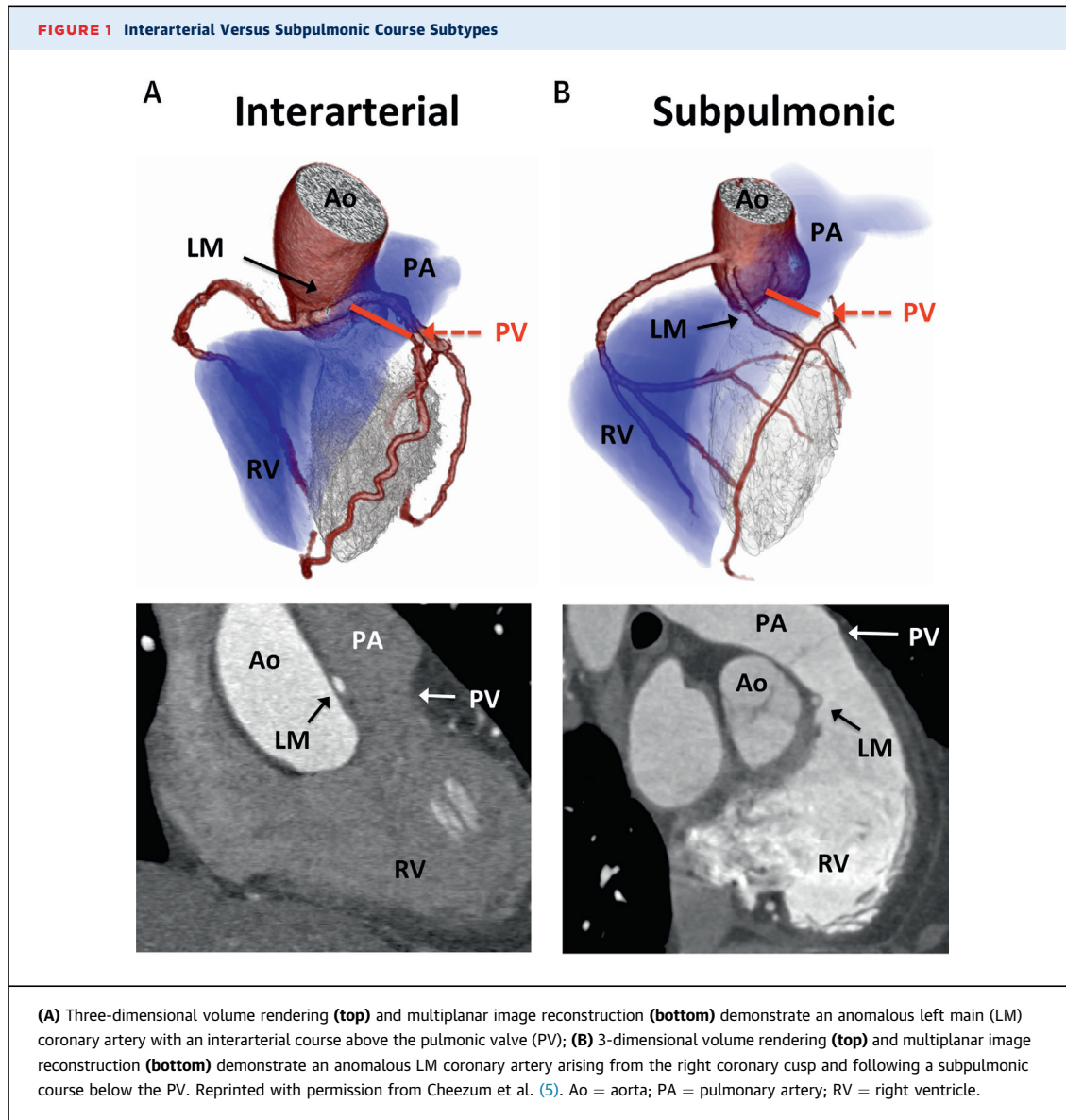
Cheezum, M.K. et al. *J Am Coll Cardiol.* 2017;69(12):1592-608.

The 5 main course subtypes of anomalous aortic origin of a coronary artery (AAOCA) arising from the inappropriate sinus are shown: **blue** = pre-pulmonic; **red** = interarterial; **orange** = subpulmonic; **green** = retroaortic; **purple** = retrocardiac. Figure prepared by Robert Cheezum and Chris Shearin (DesignVis Studios Inc., Indianapolis, Indiana), and adapted with permission from Angelini et al. (80). Ao = aorta; MV = mitral valve; PV = pulmonic valve; TV = tricuspid valve.

routine tool to image AAOCA, considering the ability of alternative noninvasive techniques to visualize CAA.

CORONARY CTA/MRA. Currently, coronary CTA and MRA are the only Class I-indicated tests used to image AAOCA (26). The choice between these techniques depends on multiple factors, including local

expertise, availability, and the strengths and limitations of these techniques (Figure 4). In many centers, CTA is preferred to image AAOCA due to rapid scan times, high spatial resolution, and lower cost in comparison to MRA. CTA has also been shown to have a high diagnostic accuracy to detect coronary artery stenosis when compared with ICA (27) and has the ability to characterize multiple AAOCA features



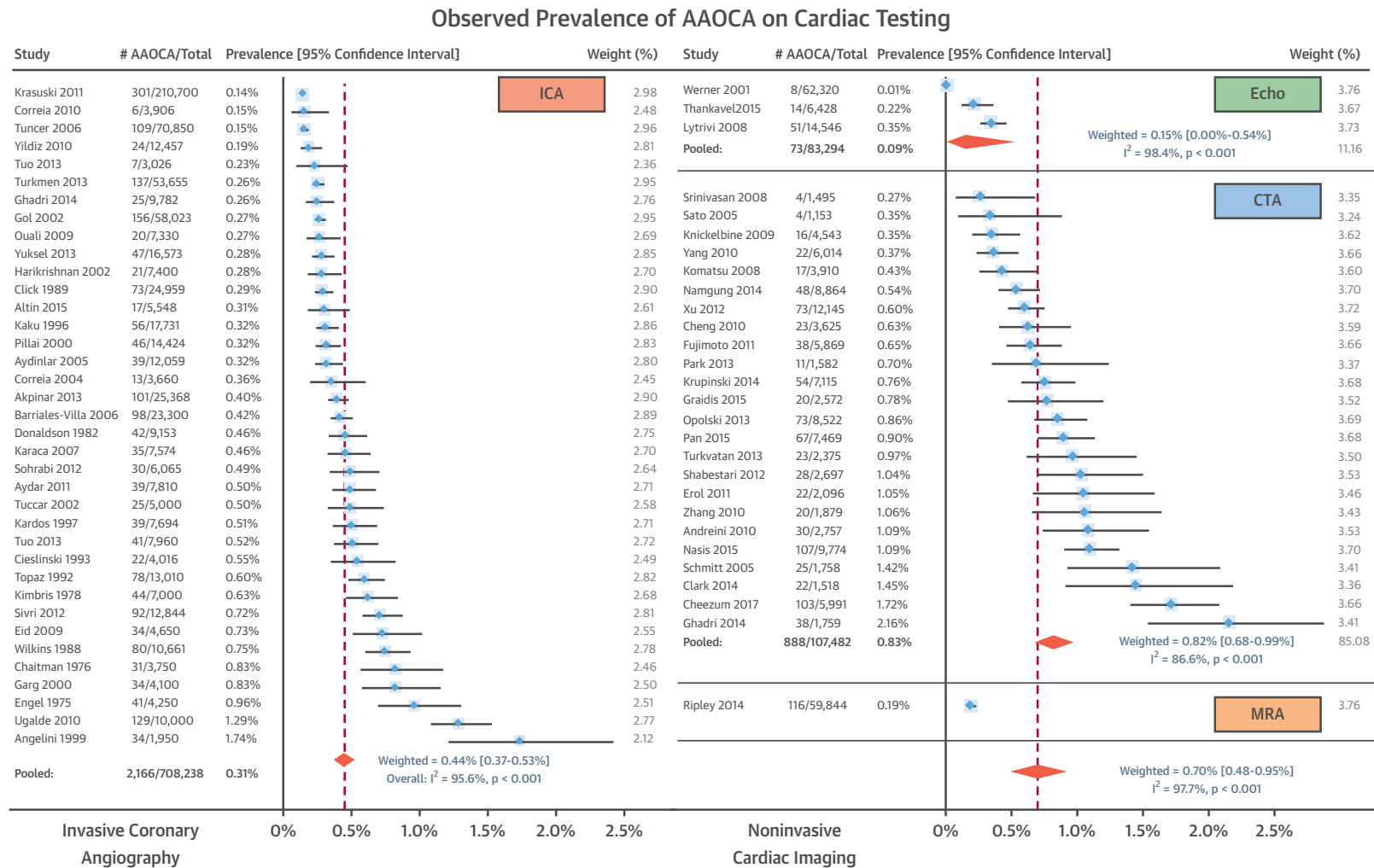
(Figure 5) (5). Although CTA incurs iodinated contrast agents and radiation exposure, dose reduction strategies (28) and CT advancements continue to improve patient safety (29). Newer scanners routinely permit very low radiation exposures (<2 mSv) (30), low contrast volumes, and rapid imaging by free-breathing without sedation in select pediatric cases (31-33). In considering CTA, the National Cancer Institute states, “for an individual child, the risks of CT are small and the individual risk-benefit balance favors the benefit when used appropriately” (34). Appropriate use criteria and guidelines support the use of contrast-enhanced CTA to assess CAA (26,35).

By comparison to CTA, MRA provides coronary artery and functional imaging without radiation or

iodinated contrast agents, but incurs lower spatial resolution, increased scan times, and higher cost. In experienced centers, free-breathing MRA visualizes the coronary takeoff and course in nearly all patients (36,37), with sedation in the majority of young children (e.g., <7 years of age) (37). In the largest MRA study, Ripley et al. (38) identified 116 AAOCA cases among 59,844 MRI scans, and they were able to determine the coronary anatomy in all patients.

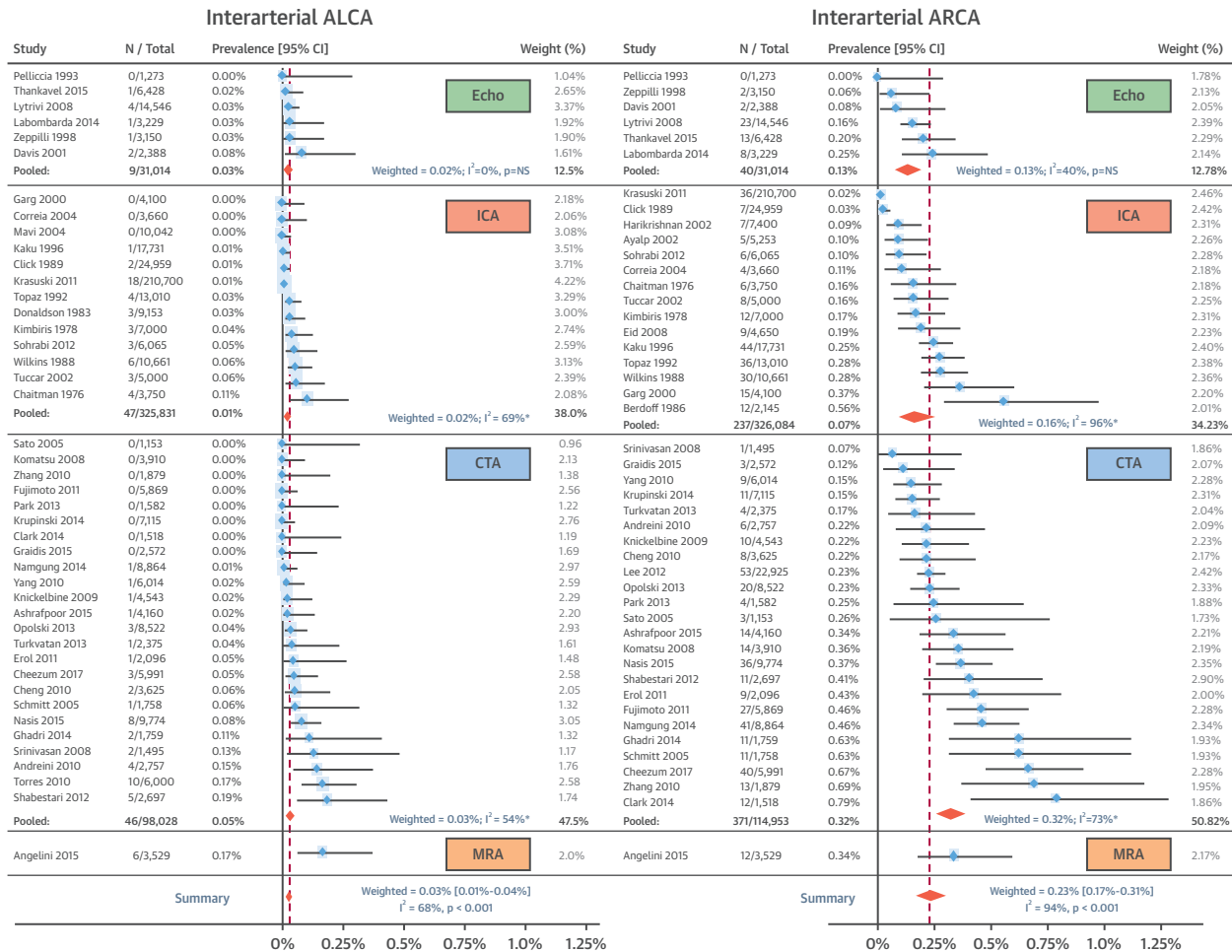
INVASIVE IMAGING. ICA is generally low risk and offers high spatial and temporal resolution. As a widely available technique with dynamic imaging, ICA has a Class IIa indication to assess CAA (Figure 4) (39). Yet ICA has known limitations in characterizing

FIGURE 2 Observed Prevalence of AAOCA Arising at or Above the Inappropriate Sinus of Valsalva on Cardiac Testing



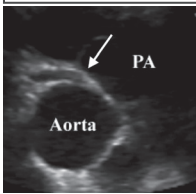
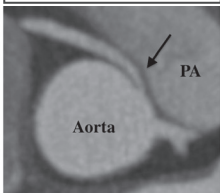
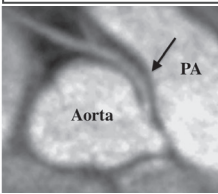
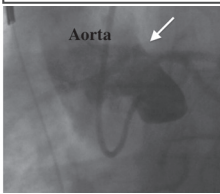
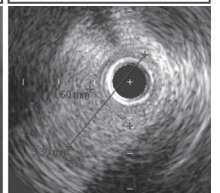
Forest plot of anomalous aortic origin of a coronary artery (AAOCA) prevalence demonstrates the combined rate of all subtypes (interarterial, subpulmonic, pre-pulmonic, retroaortic, and retrocardiac) observed by various cardiac testing methods. As described in [Online Appendix A](#), weighted transformations and 95% confidence intervals are shown in patients undergoing coronary computed tomography angiography (CTA), echocardiography (Echo), invasive coronary angiography (ICA), and magnetic resonance angiography (MRA).

FIGURE 3 Observed Prevalence of Interarterial ALCA and ARCA on Cardiac Testing



Forest plot of interarterial anomalous left coronary artery (ALCA) and anomalous right coronary artery (ARCA) prevalence observed by various cardiac testing methods. Weighted transformations and 95% confidence intervals (CI) are shown in patients undergoing CTA, Echo, ICA, and MRA. Abbreviations as in Figure 2.

FIGURE 4 Anatomic Tests Used to Characterize AAOCA Vessels

	Echo	CTA	MRA	ICA	IVUS
					
Indication for AAOCA Imaging	-	Class I	Class I	Class IIa	Class IIa
Spatial Resolution	0.8 × 1.5 mm (4-MHz transducer)	0.5 mm (isotropic)	1.0 mm (volumetric)	0.3 mm	0.15 × 0.25 mm
Temporal Resolution	30 msec	75-175 msec	60 - 120 msec	7-20 msec	Variable
Visualize surround structures	Limited	✓✓	✓	X	X
Dynamic imaging	Limited	Limited	Limited	✓ (Limited at ostium)	✓✓
Strengths	<ul style="list-style-type: none"> ✓ Noninvasive, rapid ✓ Widely available ✓ Low cost 	<ul style="list-style-type: none"> ✓ Noninvasive, rapid ✓ Visualize takeoff + course + surrounding structures ✓ Evaluate CAD ✓ Examine multiple AAOCA features * 	<ul style="list-style-type: none"> ✓ Noninvasive ✓ Visualize takeoff + course + surrounding structures ✓ Evaluate cardiac function, perfusion and prior MI ✓ Avoid radiation & iodinated contrast 	<ul style="list-style-type: none"> ✓ Availability ✓ Improved spatial and temporal resolution ✓ Ancillary techniques (IVUS, OCT, FFR) 	<ul style="list-style-type: none"> ✓ Dynamic imaging ✓ Evaluation of proximal narrowing
Limitations	<ul style="list-style-type: none"> × Limited accuracy for detection of AAOCA × Dependent on body habitus and operator technique 	<ul style="list-style-type: none"> × Limited availability × Iodinated contrast × Radiation (low dose, e.g. 2-8 mSv now routine) 	<ul style="list-style-type: none"> × Limited availability × Cost and scan-time increased vs. CTA × Spatial resolution decreased vs. CTA 	<ul style="list-style-type: none"> × Invasive; Cost × Contrast and radiation × Limited visualization of ostium, proximal course, surrounding structures 	<ul style="list-style-type: none"> × Invasive × Cost × Difficulty engaging anomalous vessel

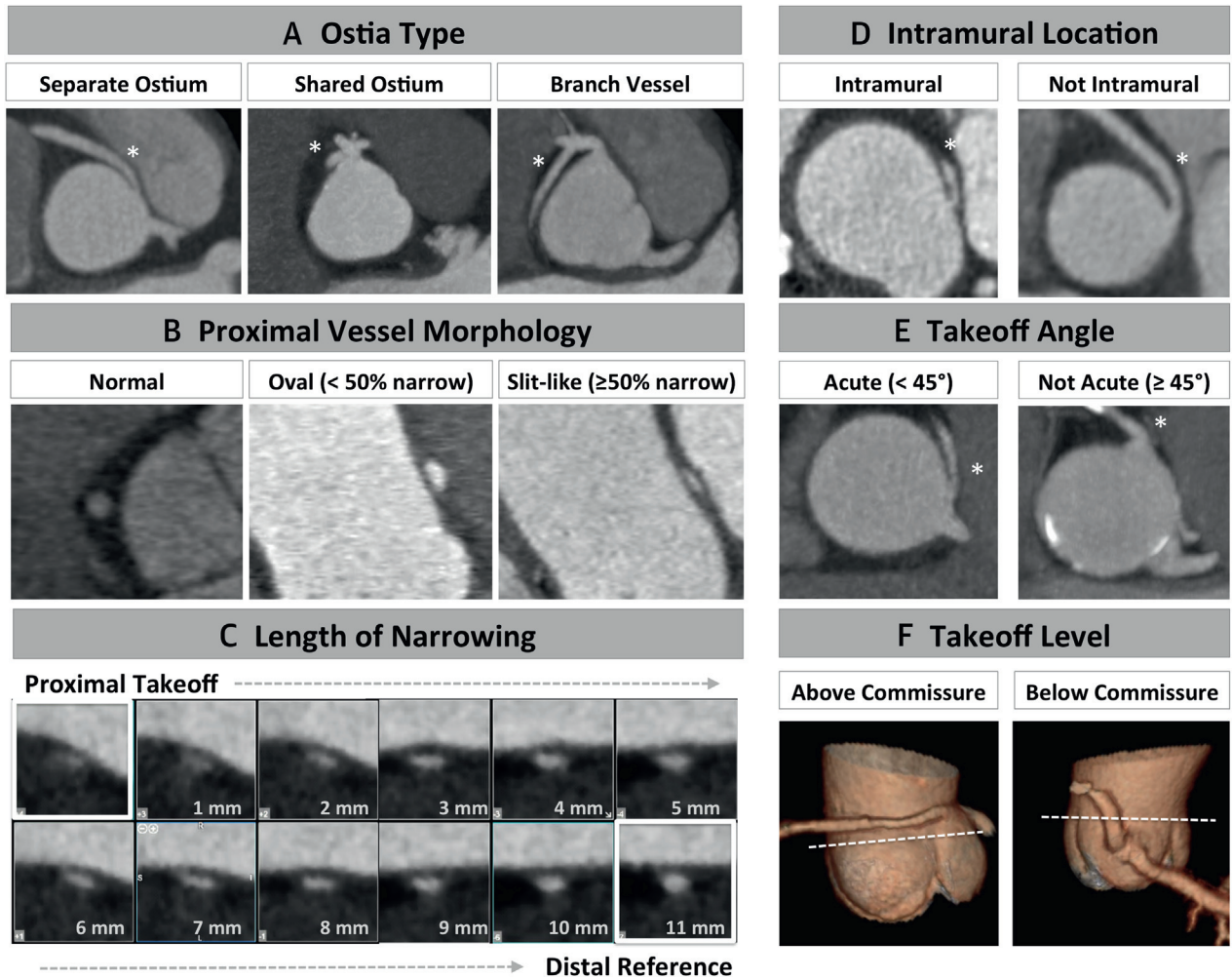
Comparison of available anatomic tests used to characterize AAOCA vessels. Adapted with permission from Angelini and Flamm (44). Echocardiography image courtesy of Daniel Shindler and Sudha Patel (Rutgers-Robert Wood Johnson Medical School, New Brunswick, New Jersey). *See Figure 5 for CTA-identified AAOCA features. CAD = coronary artery disease; FFR = fractional flow reserve; IVUS = intravascular ultrasound; MI = myocardial infarction; OCT = optical coherence tomography; other abbreviations as in Figures 1, 2, and 3.

AAOCA vessels. In a registry of 13 hospitals and 23,300 ICA cases, the initial course of anomalous coronary arteries was not identified in 41% of patients (n = 40 of 98) (40). When ICA detects AAOCA, many patients are referred for CTA or MRA to improve visualization. In our previously reported experience, 44% of AAOCA cases (n = 45 of 103) were referred for CTA after a prior ICA (5). Nonetheless, more recent use of specialized ICA catheters may improve the detection and characterization of AAOCA, particularly when combined with IVUS.

As a technique with high spatial and temporal resolution, IVUS offers excellent dynamic imaging (41,42) (Figure 4). Considering that the majority of coronary artery perfusion in left-sided epicardial vessels occurs during diastole, stenosis grading is

typically measured at the point of maximal narrowing in diastolic phase imaging. Yet systolic compression of proximal AAOCA vessels may be observed in cases with an early intramural course. As in patients with deep myocardial bridging, prolonged pressure on coronary arteries during systole and early diastole may decrease coronary blood flow. In these cases, IVUS offers superior resolution to image coronary arteries throughout the cardiac cycle and is accordingly designated as having a Class IIa indication to identify mechanisms of coronary flow restriction (26). Although IVUS is low risk, engaging AAOCA vessels may be difficult in cases with ostial narrowing, an ostial ridge, or an acute angle takeoff. Additional care is needed during IVUS to distinguish vessel spasm from true narrowing (43). In a review by Angelini and

FIGURE 5 CTA-Identified AAOCA Features



(A) Multiplanar axial computed tomography reconstruction at level of the coronary artery takeoff demonstrating AAOCA ostia types (separate ostium, shared ostium, and branch vessel). **(B)** Proximal vessel morphology in double oblique view using the percentage of lumen diameter narrowing compared with normal distal reference (not shown), stratified by normal, oval shape (<50% narrowing), and slit-like narrowing ($\geq 50\%$ narrowing). **(C)** Centerline length of vessel narrowing shown in double oblique view extending from the AAOCA vessel takeoff to the normal caliber distal reference. **(D)** Multiplanar axial reformation demonstrating AAOCA vessels with and without an intramural takeoff (proximal course within the aortic wall). **(E)** AAOCA takeoff angle obtained in the multiplanar axial reconstruction at level of the AAOCA ostium. **(F)** AAOCA vessel takeoff level (above/below aortic valve commissure) shown in 3-dimensional reformatted images. *Denotes anomalous coronary artery. Adapted with permission from Cheezum et al. (5). Abbreviations as in Figure 2.

Flamm (44), 3 of 31 patients (10%) with AAOCA undergoing IVUS developed ischemia refractory to nitroglycerin, requiring stent placement or catheter removal. Lastly, optical coherence tomography may have a role in imaging of AAOCA vessels with superior spatial resolution (36), although future studies are needed to examine the use of optical coherence tomography in these patients.

FRACTIONAL FLOW RESERVE. Although not routinely used to evaluate AAOCA, fractional flow

reserve (FFR) may offer an adjunct to determine the functional significance of AAOCA narrowing. Lee et al. (45) examined 37 consecutive adult patients (median age 54 years, range 18 to 75 years) with interarterial ARCA by invasive FFR. Despite symptoms in the majority of patients (83%), only 1 patient (3%) had a significantly reduced FFR at rest (<0.80), whereas 3 patients (8%) developed a significant reduction in FFR (to <0.80) with dobutamine. These findings suggest that (in adults) many interarterial ARCA cases may not be physiologically significant or

TABLE 1 Autopsy Studies of SCD in ARCA/ALCA Patients

First Author, Year (Ref. #)	Total Number of Autopsy Patients With ARCA/ALCA		Coronary-Related SCD		% of ARCA/ALCA Deaths During Exercise	% of ARCA/ALCA Asymptomatic Before Death
	ARCA	ALCA	ARCA (%)	ALCA (%)		
Cheitlin et al., 1974 (55)	18	33	0 of 18 (0)	9 of 33 (27)	78	*
Kragel and Roberts, 1988 (56)	25	7	8 of 25 (32)	5 of 7 (71)	*	38
Taylor et al., 1992 (57)	24	28	*	23 of 28 (82)	*	66
Taylor et al., 1997 (58)	21	9	4 of 21 (19)	8 of 9 (89)	83	66
Frescura et al., 1998 (59)	7	4	4 of 7 (57)	4 of 4 (100)	75	50

*Not reported. Adapted with permission from Mirchandani and Phoon (6).
ALCA = anomalous left coronary artery; ARCA = anomalous right coronary artery; SCD = sudden cardiac death.

may be associated with more transient mechanisms of ischemia (46,47). Recognizing rare, but potential difficulties with invasive testing, Lee et al. (45) noted that 1 patient developed an ostial ARCA dissection during ICA, and placement of a guiding catheter was not possible in 2 patients.

NONINVASIVE FUNCTIONAL TESTING. Several studies have assessed the functional significance of AAOCA by exercise treadmill testing and stress myocardial perfusion imaging (5,48-53). Gräni et al. (54) examined 46 adults (mean age 56 ± 12 years) with CTA-identified AAOCA (26 interarterial, 20 other) by single-photon emission computed tomography and found that myocardial ischemia or scar was only present in patients with concomitant coronary artery disease. Notably, vasodilator testing was used in 50% of patients. Yet exercise stress is preferable for evaluating patients with AAOCA when considering that a majority of SCD cases attributed to AAOCA occur with strenuous exercise (Table 1) (6,55-60). Nonetheless, both exercise treadmill testing and stress myocardial perfusion imaging may yield false-positive and false-negative results (46,47,61). Among 27 young athletes with AAOCA (23 ALCA, 4 ARCA) described by Basso et al. (62), 6 patients had a normal exercise treadmill test before SCD. Consequently, the absence of ischemia during stress testing cannot be viewed as reassuring currently, particularly when potentially high-risk anatomic features are present (i.e., proximal vessel narrowing) (5,26). Ongoing studies are needed to define the optimal approach to risk stratification of these patients and to compare the accuracy of various tests used to detect AAOCA narrowing and ischemia.

OUTCOMES

SUDDEN CARDIAC DEATH. To date, several autopsy studies have demonstrated that interarterial ALCA and ARCA patients are associated with an increased

risk of SCD (Table 1). By these studies, the risk of SCD appears highest in young individuals and particularly in interarterial ALCA, during or following a period of strenuous exertion. A significant portion (38% to 66%) of ALCA and ARCA patients have no reported symptoms before sudden death, thus limiting efforts to detect these patients antemortem. Despite this, the incidence of SCD from CAA in large cohorts of young athletes and screening populations is exceedingly rare (Table 2). Given the rarity of these cases, current guidelines do not support universal pre-participation cardiac testing to screen for AAOCA in asymptomatic athletes (63). This remains an evolving issue, with studies and clarification needed to consider screening options. Currently, the American Heart Association and American Academy of Pediatrics offer various tools for individualized risk assessment (64,65). Additionally, a multidisciplinary task force held by the National Collegiate Athletic Association provided a recent consensus statement on cardiovascular care of college athletes (66).

OUTCOME STUDIES: REVASCUARIZATION VERSUS CONSERVATIVE MANAGEMENT.

To examine outcomes of interarterial ALCA and ARCA patients, we performed a comprehensive review of published data using detailed methods and inclusion and exclusion criteria as described in Online Appendix B. Among 5,459 abstracts in our initial search of published reports, we identified 20 studies reporting outcomes (death, revascularization, symptoms, and/or myocardial infarction) with at least 20 ALCA/ARCA patients and >1 year of follow-up (Online Figure 2). As described in Table 3, the incidence of AAOCA-related death in available follow-up is rare, incorporating evidence from 8 imaging cohorts, 10 selected revascularization cohorts (9 surgical, 1 percutaneous coronary intervention [PCI]), and 2 systematic reviews. Notably, only 2 included studies in adult cohorts of

TABLE 2 Population Studies of SCD

First Author, Year (Ref. #)	Population	N	Study Duration, yrs	Sudden Deaths		Deaths Attributed to CAA	
				Total, n (%)	Cardiac, n	n	Incidence
Wren et al., 2000 (81)	England, children 1 to 20 years of age	806,000	10	270 (0.03)	26	0	0
Eckart et al., 2004 (82)	U.S. military recruits	6,300,000	25	126 (0.002)	64	21	1 in 300,000
Corrado et al., 2006 (83)	Italy, population 12-35 yrs of age	4,379,900	26	*	320	21	1 in 208,567
Redelmeier and Greenwald, 2007 (84)	Runners from 26 U.S. marathons	3,292,268	30	26 (0.0008)	21	2	1 in 1,646,134
Maron et al., 2009 (85)	U.S. competitive athletes	*	27	1,866 (*)	1,049	119	*
Chugh et al., 2009 (86)	Oregon county, children ≤17 years of age	660,486†	3	8 (*)	3	0	*
Harris et al., 2010 (87)	U.S. triathletes	959,214	3	14 (0.001)	7	1	1 in 959,214
Harmon et al., 2011 (88)	NCAA athletes	393,932	5	80 (0.02)	45	*	*

*Not reported. †Total population of Multnomah County, Oregon, including children and adults. Adapted with permission from Peñalver et al. (89).
 CAA = coronary artery anomalies (comprising all types of CAA; anomalous aortic origin of a coronary artery subtype not reported); NCAA = National Collegiate Athletic Association; SCD = sudden cardiac death.

predominantly ARCA patients (>97%) have examined a primary approach of conservative therapy, observing a very low mortality rate (<1%) in 1.3 to 5.6 years of follow-up (48,67). Nonetheless, available studies suggest that surgical repair offers a safe and effective option to relieve symptoms. Among large surgical cohorts including predominantly ARCA patients, Mainwaring et al. (51) demonstrated that surgical repair appears safe and effective to relieve symptoms in up to 97% of patients during follow-up. Similarly, in a systematic review of 325 ALCA patients with follow-up after surgical repair, Nguyen et al. (68) described a 9% morbidity rate with very low cardiac mortality (<1% of patients). In that study, 2.2% of patients experienced symptoms post-operatively. Conversely, in a study by Opolski et al. (67), 27% (n = 19 of 70) of patients with AAOCA managed conservatively reported an increase in chest pain and/or diminished exercise tolerance during follow-up. Notably, ARCA patients with interarterial compression had more syncope (33% vs. 9%, p = 0.041) and a trend toward more chest pain (50% vs. 19%, p = 0.058) in follow-up compared with AAOCA without interarterial compression.

MANAGEMENT

RECOMMENDATIONS FOR MANAGEMENT. Patients with AAOCA and a noninterarterial course subtype (i.e., pre-pulmonic, subpulmonic, retroaortic, retrocardiac) typically have an excellent prognosis. In these cases, clinical presentation remains key to guide the need for further evaluation and management (if any). Recommendations for AAOCA

management remain an evolving topic, with particular debate regarding the indications for surgical repair of the interarterial ALCA and ARCA course subtypes (69,70). To review, the American College of Cardiology/American Heart Association 2008 guidelines for the management of adults with congenital heart disease (Table 4, Available Recommendations section) recommended revascularization for interarterial ALCA, regardless of ischemia or symptoms (26). Similarly, surgical repair was recommended for ARCA patients with a “course between the great arteries or in an intramural fashion” (26) in the presence of documented ischemia. Revascularization was also considered beneficial in patients with vascular wall hypoplasia or obstruction to coronary flow, even in the absence of ischemia (26).

Despite these prior recommendations, considerable debate remains regarding the optimal management of patients with interarterial ARCA or ALCA (69). Consequently, our approach to these patients relies on numerous factors to guide management, starting with a thorough history to guide individual risk assessment (64,65). In all cases of clinically suspected interarterial ALCA or ARCA, we recommend imaging with CTA (or MRA) to visualize anatomic features that may guide decision making for surgical repair (e.g., evidence of proximal vessel obstruction). In symptomatic patients with a compelling presentation (e.g., a history of aborted SCD, documented ischemia, exertional syncope, or chest pain) and any degree of proximal vessel narrowing in an ectopic artery, we recommend a multidisciplinary discussion to consider surgical repair. The risk of SCD appears highest among patients with interarterial ALCA

TABLE 3 Outcomes of Interarterial ARCA/ALCA Patients (Studies With ≥20 Patients and at Least 1 Year of Follow-Up)

First Author, Year (Ref. #)	Year	Population	Age, yrs	Total N (ARCA/ALCA)	Follow-Up, yrs	Surgery (n) (ARCA/ALCA)	PCI (n) (ARCA/ALCA)	Comments/Morbidity
Imaging Cohorts								
Kaku et al. (48)	1996	17,731 adults referred for ICA	56 ± 12	44 (44/0)	5.6 ± 4.2	0 (0/*)	*	All patients treated conservatively and no deaths attributed to ARCA.
Lytrivi et al. (90)	2008	14,546 children referred for TTE	4 ± 5	27 (23/4)	2.5 ± 3.0	6 (5/1)	*	No deaths attributed to ARCA/ALCA among 22 patients with follow-up.
Krasuski et al. (91)	2011	210,700 adults referred for ICA	58 ± 14	54 (36/18)	9.2 [4.5-16.1]	28 (20/8)	*	Among 301 AAOCA, similar all-cause mortality with surgery (n = 36 of 94, 38%) vs. no surgery (n = 95 of 207, 46%). Among 54 IAC, lower all-cause mortality with surgery (n = 5 of 28, 18%) vs. no surgery (n = 12 of 26, 46%), but underpowered for comparison. No perioperative deaths occurred.
Lee et al. (92)	2012	22,925 adults referred for CTA 53 IAC vs. 34 subpulmonic ARCA	56 ± 12	53 (53/*)	2.5 [0.8-3.9]	8 (8/*)	*	1 CV death, 3 nonfatal MI, 8 UA in follow-up among 53 with IAC. Angina more common in IAC group vs. subpulmonic course (43% vs. 6%, p = 0.001)
Opolski et al. (67)	2013	8,522 adults referred for CTA	56 ± 13	22 (20/2)	1.3 ± 1.0	2 (1/1)	*	Among 72 AAOCA, 97% (n = 70 of 72) conservatively managed, with no deaths or MI attributed to AAOCA; 27% had worsened symptoms. Syncope more common in IAC compared with no IAC (33% vs. 9%, p = 0.04).
Ripley et al. (38)	2014	59,844 adults referred for MRA	54 [40-64]	64 (†/†)	4.3 [2.5-7.8]	23 (†/†)	*	13 single coronaries with unclear course.† 3 deaths not attributed to IAC.
Nasis et al. (49)	2015	9,774 adults referred for CTA	58 ± 13	44 (36/8)	2.3 ± 1.3	9 (6/3)	*	No cardiac deaths or acute coronary syndrome in follow-up.
Cheezum et al. (5)	2017	5,992 adults referred for CTA	52 ± 17	43 (40/3)	5.8 [3.8-7.8]	13 (12/1)	*	2 late (≥90-day) CV deaths in ARCA patients, not attributed to ARCA vessel.
Revascularization Cohorts								
Osaki et al. (53)	2008	31 ARCA/ALCA patients; subset of 7 ALCA with surgery	6 ± 7	31 (18/13)	4.8†/1.9†	7 (0/7)	*	1 patient with symptoms after surgery; 1 cardiac death (care withdrawn POD1 for neurological impairment after resuscitation); No surgery/ surgery.†
Davies et al. (93)	2009	36 ARCA/ALCA surgical repair	44 ± 16	36 (21/15†)	1.1 ± 2.8	36 (21/15)	*	2 LAD included;† 1 (3%) recurrent symptoms; 1 death from subdural bleed.
Frommelt et al. (94)	2011	27 ARCA/ALCA surgical repair	13 ± 4	27 (20/7)	1.8 [*]	27 (20/7)	*	No ischemic symptoms or deaths in follow-up. 7 patients with trivial AI.
Mumtaz et al. (95)	2011	22 ARCA/ALCA unroofing	15 [*]	22 (15/7)	1.4 [*]	22 (15/7)	*	1 (5%) with chest pain but normal ICA post-operatively. No deaths in follow-up.
Kaushal et al. (96)	2011	27 ARCA/ALCA surgical repair	14 ± 12	27 (25/2)	1.2 ± 0.1	27 (25/2)	*	2 (7%) with noncardiac symptoms. No deaths or significant morbidity.
Mainwaring et al. (51)	2014	74 ARCA/ALCA surgical repair	15 [*]	74 (47/27)	6.0 [*]	74 (47/27)	*	1 heart transplant; remaining patients free of cardiac symptoms. No deaths.
Wittlieb-Weber et al. (97)/ Brothers et al. (52)	2014/2007	24 ARCA/ALCA surgical repair	12 [*]	24 (16/8)	5.3 [*]	24 (16/8)	*	13 (54%) with follow-up symptoms, none with ischemia. Normal quality of life when reported (n = 12). No deaths, 1 emergent reoperation POD1, 2 post-operative infections, 4 mild AI, 11 effusions (1 requiring drainage).

Continued on the next page

and, in selected individuals, the benefits of revascularization likely outweigh the benefits of surgery. Conversely, a conservative approach may be reasonable in asymptomatic individuals with interarterial ARCA, no proximal vessel narrowing, and no evidence of ischemia. Ultimately, we recognize that the optimal management strategy likely varies as a function of individual age, presentation, anatomy, and physiology.

SURGICAL REPAIR. When a decision is made to pursue surgical repair, evidence suggests that coronary artery bypass graft should be avoided in the absence of concomitant obstructive coronary artery disease, given the potential for competitive flow from native vessels to cause graft failure. Although a discussion of surgical repair techniques is beyond the scope of this review, coronary unroofing is generally preferred in patients with an early intramural course, when feasible. Alternatively, coronary reimplantation, fenestration, neo-ostia formation, or combination techniques provide additional options. In all cases, care must be taken to avoid iatrogenic injury to the aortic valve commissure and its support.

PERCUTANEOUS CORONARY INTERVENTION. Limited evidence exists regarding the use of PCI in patients with interarterial ALCA or ARCA. In a study of 42 predominantly adult patients (mean age 48 years, range 12 to 73 years) with interarterial ARCA undergoing PCI, the rate of in-stent restenosis was 13% by serial IVUS (42). In that study, 29% of patients had recurrent symptoms during a median follow-up period of 5 years. Although coronary artery bypass graft guidelines acknowledge that PCI has been used in adults with anomalous coronary arteries (71), a recent American College of Cardiology/American Heart Association Task Force recommends, “surgical procedures are the only therapies available for correcting these anomalies” (72). Consequently, PCI is currently not considered a routine option for revascularization in these patients.

EXERCISE RESTRICTION

Recommendations for exercise and disqualification from competitive sports were the subjects of the 2015 American College of Cardiology/American Heart Association updated scientific statement (Table 4, Available Recommendations section) (72). In ARCA patients with symptoms, arrhythmias, or ischemia on exercise testing, restriction from all competitive sports is recommended while awaiting surgical repair. Conversely, in ARCA patients without symptoms or a positive exercise stress test, “permission to compete can be considered after adequate counseling of the

		Revascularization Cohorts				Reviews	
Sharma et al. (98)	2014	75 ARCA/ALCA unroofing	40 ± 20	75 (69/6)	1.6 ± 0.2	75 (69/6)	* 1 (1%) late noncardiac death. No cardiac symptoms at follow-up.
Angelini et al. (42)	2015	67 ARCA w/IVUS; 42 PCI, 3 surgery, 22 medical therapy	48 ± 12	67 (67/*)	5.0 ± 2.9	3 (3/*)	42 (42/*) Symptoms improved in PCI subset. No ARCA related deaths. n = 10 had clinically indicated follow-up ICA, including n = 4 with in-stent restenosis (n = 2 BMS, n = 2 DES) and n = 1 with late-stent thrombosis.
Feins et al. (99)	2016	259 patients with AAOCA; 61 with surgery, 29 ARCA/ALCA	43 ± 3	29 (24/5)	3.8 ± 0.8	29 (24/5)	* 97% free of symptoms attributed to coronary anomaly; 1 death from endocarditis of a prosthetic valve. No perioperative deaths.
Moustafa et al. (100)	2008	264 ALCA (130 autopsy, 62 with no follow-up, 72 with follow-up)	36 ± 22	72 (*/72)	1.7†	57 (*/57)	4 (*/4) 1 (2%) with severe AI after ALCA unroofing, otherwise no significant operative morbidity. No deaths in follow-up. Weighted average.†
Nguyen et al. (68)	2012	326 ALCA surgical repair	*	326 (*/326)	0-14	326 (*/326)	* 2.2% symptoms, 9.2% morbidity, 0.6% cardiac death (n = 2 of 325) in follow-up

Values are mean ± SD [IQR] unless otherwise indicated. *Not applicable or not reported. †Median value.
AAOCA = anomalous aortic origin of the coronary artery; AI = aortic insufficiency; BMS = bare-metal stent; CTA = computed tomography angiography; CV = cardiovascular; DES = drug-eluting stent; F/U = follow-up; IAC = interarterial course; ICA = invasive coronary angiography; IVUS = intravascular ultrasound; LAD = left anterior descending artery; MRA = magnetic resonance angiography; MI = myocardial infarction; PCI = percutaneous coronary intervention; POD = post-operative day; SD = standard deviation; TTE = transthoracic echocardiogram; UA = unstable angina; other abbreviations as in Table 1.

TABLE 4 Management of Interarterial ALCA/ARCA and Key Knowledge Gaps		
Available Recommendations in Interarterial ALCA/ARCA Management		
Class	2011 ACC/AHA Guideline for CABG (71) and 2008 ACC/AHA Guidelines for Management of ACHD (26)	2015 ACC/AHA Scientific Statement for Competitive Athletes With Cardiovascular Abnormalities (72)
I	Surgical coronary revascularization for: –Anomalous left main with an interarterial course –Ischemia due to coronary compression (when coursing between the great arteries or in intramural fashion) –Interarterial ARCA and evidence of ischemia.	–
Ila	Surgical revascularization can be beneficial if there is vascular wall hypoplasia or obstruction to coronary flow, regardless of inability to document ischemia.	ARCA patients should be evaluated by an exercise stress test. If normal stress test and no symptoms, permission to compete can be considered after counseling and considering uncertain accuracy of a negative stress test.
Ilib	Surgical coronary revascularization may be reasonable in patients with anomalous left anterior descending with a course between the aorta and PA.	After successful surgical repair of ALCA/ARCA, athletes may consider participation in all sports 3 months after surgery if free of symptoms and an exercise stress test shows no evidence of ischemia or cardiac arrhythmias.
III	–	Restrict ALCA patients from all competitive sports, regardless of symptoms, before surgical repair, with possible exception of Class IA sports.* Restrict ARCA patients from all competitive sports before surgical repair if symptoms, arrhythmias, or signs of ischemia on exercise stress testing, with possible exception of Class IA sports.*
Key Knowledge Gaps in AAOCA patients		
<ol style="list-style-type: none"> 1. Do surgical repair, medical management, and/or exercise restriction affect the natural history of interarterial ALCA and ARCA? 2. Do the risks of surgical repair outweigh potential long-term benefits? 3. What is the optimal technique for AAOCA repair considering individual anatomy (e.g., intramural course, relation to commissure)? 4. How should anatomic vs. functional testing guide risk stratification and management? 5. Is there a role for other testing (e.g., MRI evaluation for scar, event monitoring) to risk stratify interarterial ALCA and ARCA patients? 6. What is the comparative accuracy of tests used to identify AAOCA origin, course, and anatomic features (i.e., intramural course)? 7. What degree of proximal vessel narrowing defines obstruction in AAOCA vessels? 8. What is the true prevalence of AAOCA and the absolute risk of SCD associated with it in the general population? 9. Consensus terminology and precise characterization of AAOCA are needed throughout published reports. 10. Objective and clearly defined endpoints are needed to examine outcomes in AAOCA patients with prospective follow-up. 		
<p>*IA sports: for example, bowling, cricket, golf, curling, riflery, yoga (101).</p> <p>ACC = American College of Cardiology; ACHD = adult congenital heart disease; AHA = American Heart Association; CABG = coronary artery bypass graft; MRI = magnetic resonance imaging; PA = pulmonary artery; other abbreviations as in Tables 1 and 3.</p>		

athlete and/or the athlete's parents as to the risk and benefit, taking into consideration the uncertainty of a negative stress test" (72). Additionally, exceptions may be made for participation in Class IA sports (i.e., bowling, cricket, golf, curling, riflery, yoga).

In athletes with ALCA, "especially cases where the artery passes between the pulmonary artery and aorta" (72), restriction from all competitive sports is recommended (with the possible exception of Class IA sports) while awaiting surgical repair. After surgery, a return to intense activities may be considered if the patient remains asymptomatic and an exercise stress test shows no evidence of ischemia or cardiac arrhythmias.

FUTURE DIRECTIONS

In considering available evidence and recommendations in AAOCA management, we recognize that several key knowledge gaps remain and require further study (Table 4, Key Knowledge Gaps section). To examine these knowledge gaps, several

collaborations are underway to improve our understanding of these patients. The CHSS Registry of AAOCA is a multicenter study examining outcomes of patients (age ≤ 30 years) with AAOCA managed by observation or surgery (73). CHSS includes AAOCA patients with an interarterial, intraseptal, and/or intramural course. The registry consists of a retrospective cohort (diagnosis between January 1998 and January 2009), and a prospective cohort diagnosed after January 2009. As of January 2014, 378 patients with AAOCA are included from 35 institutions (74), incorporating patients from the Society of Thoracic Surgeons Congenital Heart Surgery Database (75).

The registry of proximal anomalous connections of coronary arteries (ANOCOR) of the French Society of Cardiology is a prospective multicenter observational study of patients ≥ 15 years of age with ANOCOR diagnosed by ICA or CTA (76). Aims are to examine strategies used to treat ANOCOR and their impact on morbidity and mortality at 5-year follow-up with scheduled completion in January 2018. As of February 2015, the registry is composed of 472 patients

(mean age 63 ± 13 years, range 16 to 95 years of age), including 451 (91%) with AAOCA among various ANOCOR subtypes (77).

Incorporating AAOCA among other causes of SCD in young patients, the Sudden Death in the Young Registry (78) will further aid studies of the incidence and mechanisms of SCD (79). With these collaborations, key knowledge gaps may be addressed to inform public efforts and consensus guidelines, with a common goal to improve AAOCA recognition and management and prevent SCD.

CONCLUSIONS

The risk of SCD appears highest among patients with interarterial ALCA and, in selected individuals, the benefits of revascularization likely outweigh the risks of surgery. However, in many individuals with ARCA and an interarterial course, a conservative approach may be reasonable, particularly in older patients with no proximal vessel narrowing and no signs or symptoms of ischemia. Nevertheless, the optimal approach to risk stratification and management for many

AAOCA patients remains uncertain. Recognizing the inherent variability in patient factors, as well as institutional and provider preferences, an individualized approach is recommended.

ACKNOWLEDGMENTS The authors are grateful to Robert Cheezum and Chris Shearin (DesignVis Studios Inc., Indianapolis, Indiana) for their contribution of the **Central Illustration**; Daniel Shindler and Sudha Patel (Rutgers-Robert Wood Johnson Medical School, New Brunswick, New Jersey) for their contribution of the echocardiography image in **Figure 4**; and Dr. Justin Dunn (Summa Health System, Akron, Ohio) and Hunain Shiwani (Leeds General Infirmary, Leeds, United Kingdom) for their feedback and assistance in the preparation of the manuscript.

ADDRESS FOR CORRESPONDENCE: Dr. Michael K. Cheezum, Brigham and Women's Hospital, Harvard Medical School, Departments of Medicine and Radiology (Cardiovascular Division), 75 Francis Street, Boston, Massachusetts 02115. E-mail: mcheezum@gmail.com.

REFERENCES

1. Angelini P. Coronary artery anomalies: an entity in search of an identity. *Circulation* 2007;115:1296-305.
2. Jacobs ML, Mavroudis C. Anomalies of the coronary arteries: nomenclature and classification. *Cardiol Young* 2010;20 Suppl 3:15-9.
3. Brothers JA, Gaynor JW, Jacobs JP, et al. The registry of anomalous aortic origin of the coronary artery of the Congenital Heart Surgeons' Society. *Cardiol Young* 2010;20 Suppl 3:50-8.
4. Lipton MJ, Barry WH, Obrez I, Silverman JF, Wexler L. Isolated single coronary artery: diagnosis, angiographic classification, and clinical significance. *Radiology* 1979;130:39-47.
5. Cheezum MK, Ghoshhajra B, Bittencourt MS, et al. Anomalous origin of the coronary artery arising from the opposite sinus: prevalence and outcomes in patients undergoing coronary CTA. *Eur Heart J Cardiovasc Imaging* 2017;18:224-35.
6. Mirchandani S, Phoon CK. Management of anomalous coronary arteries from the contralateral sinus. *Int J Cardiol* 2005;102:383-9.
7. Liberthson RR, Dinsmore RE, Bharati S, et al. Aberrant coronary artery origin from the aorta: diagnosis and clinical significance. *Circulation* 1974;50:774-9.
8. Pelliccia A, Spataro A, Maron BJ. Prospective echocardiographic screening for coronary artery anomalies in 1,360 elite competitive athletes. *Am J Cardiol* 1993;72:978-9.
9. Zeppilli P, dello Russo A, Santini C, et al. In vivo detection of coronary artery anomalies in asymptomatic athletes by echocardiographic screening. *Chest* 1998;114:89-93.
10. Park JH, Kwon NH, Kim JH, et al. Prevalence of congenital coronary artery anomalies of Korean men detected by coronary computed tomography. *Korean Circ J* 2013;43:7-12.
11. Angelini P, Cheong B, Uribe C, et al. Results of systematic MRI-based pre-participation screening of school children: the sample size issue (abstr). *J Am Coll Cardiol* 2015;65:A1305.
12. Prakken NH, Cramer MJ, Olimulder MA, Agostoni P, Mali WP, Velthuis BK. Screening for proximal coronary artery anomalies with 3-dimensional MR coronary angiography. *Int J Cardiovasc Imaging* 2010;26:701-10.
13. Thankavel PP, Lemler MS, Ramaciotti C. Utility and importance of new echocardiographic screening methods in diagnosis of anomalous coronary origins in the pediatric population: assessment of quality improvement. *Pediatr Cardiol* 2015;36:120-5.
14. Brothers JA, Whitehead KK, Keller MS, Fogel MA, Paridon SM, Weinberg PM, Harris MA. Cardiac MRI and CT: differentiation of normal ostium and intraseptal course from slitlike ostium and interarterial course in anomalous left coronary artery in children. *AJR Am J Roentgenol* 2015;204:W104-9.
15. Lorber R, Srivastava S, Wilder TJ, et al., for the AAOCA Working Group of the Congenital Heart Surgeons Society. Anomalous aortic origin of coronary arteries in the young: echocardiographic evaluation with surgical correlation. *J Am Coll Cardiol Img* 2015;8:1239-49. [Published correction appears in *J Am Coll Cardiol Img* 2016;9:217.]
16. Sasson Z, Grande P, Lorette I, McEwan P. Proximal narrowing of anomalous right coronary artery from the left coronary sinus: delineation by omniplane transesophageal echocardiogram. *Can J Cardiol* 1996;12:529-31.
17. Kaku B, Shimizu M, Kita Y, Yoshio H, Ino H, Takeda R. Detection of anomalous origin of the left coronary artery by transesophageal echocardiography and magnetic resonance imaging. *Jpn Heart J* 1994;35:383-8.
18. Fernandes F, Alam M, Smith S, Khaja F. The role of transesophageal echocardiography in identifying anomalous coronary arteries. *Circulation* 1993;88:2532-40.
19. Giannoccaro PJ, Sochowksi RA, Morton BC, Chan KL. Complementary role of transoesophageal echocardiography to coronary angiography in the assessment of coronary artery anomalies. *Br Heart J* 1993;70:70-4.
20. Alam M, Brymer J, Smith S. Transesophageal echocardiographic diagnosis of anomalous left coronary artery from the right aortic sinus. *Chest* 1993;103:1617-8.
21. Henson KD, Geiser EA, Billett J, Alexander JA, Akins EW, Bopitiya C. Use of transesophageal echocardiography to visualize an anomalous right coronary artery arising from the left main coronary artery (single coronary artery). *Clin Cardiol* 1992;15:462-5.
22. Gaither NS, Rogan KM, Stajduhar K, Banks AK, Hull RW, Whitsiff T, Vernalis MN. Anomalous origin and course of coronary arteries in adults: identification and improved imaging utilizing transesophageal echocardiography. *Am Heart J* 1991;122:69-75.
23. Salloum JA, Thomas D, Evans J. Transoesophageal echocardiography in diagnosis of

- aberrant coronary artery. *Int J Cardiol* 1991;32:106-8.
24. Balaguru D, Auslender M, Colvin SB, Rutkowski M, Artman M, Phoon CK. Intraoperative myocardial ischemia recognized by transesophageal echocardiography monitoring in the pediatric population: a report of 3 cases. *J Am Soc Echocardiogr* 2000;13:615-8.
 25. Yilmaz H, Gungor B, Sahin S, Bolca O. A case of anomalous origin of circumflex artery from right sinus of Valsalva recognized by three-dimensional transesophageal echocardiography and coronary computed tomography angiography. *Heart Views* 2014;15:57-9.
 26. Warnes CA, Williams RG, Bashore TM, et al. ACC/AHA 2008 guidelines for the management of adults with congenital heart disease: a report of the American College of Cardiology/American Heart Association Task Force on Practice Guidelines (Writing Committee to Develop Guidelines on the Management of Adults With Congenital Heart Disease): developed in collaboration with the American Society of Echocardiography, Heart Rhythm Society, International Society for Adult Congenital Heart Disease, Society for Cardiovascular Angiography and Interventions, and Society of Thoracic Surgeons. *J Am Coll Cardiol* 2008;52:e143-263.
 27. Budoff MJ, Dowe D, Jollis JG, et al. Diagnostic performance of 64-multidetector row coronary computed tomographic angiography for evaluation of coronary artery stenosis in individuals without known coronary artery disease: results from the prospective multicenter ACCURACY (Assessment by Coronary Computed Tomographic Angiography of Individuals Undergoing Invasive Coronary Angiography) trial. *J Am Coll Cardiol* 2008;52:1724-32.
 28. Halliburton SS, Abbara S, Chen MY, et al., for Society of Cardiovascular Computed Tomography. SCCT guidelines on radiation dose and dose-optimization strategies in cardiovascular CT. *J Cardiovasc Comput Tomogr* 2011;5:198-224.
 29. Chinmalyan KM, Boura JA, DePetris A, et al., for the Advanced Cardiovascular Imaging Consortium Coinvestigators. Progressive radiation dose reduction from coronary computed tomography angiography in a statewide collaborative quality improvement program: results from the Advanced Cardiovascular Imaging Consortium. *Circ Cardiovasc Imaging* 2013;6:646-54.
 30. Ghoshhajra BB, Lee AM, Engel LC, et al. Radiation dose reduction in pediatric cardiac computed tomography: experience from a tertiary medical center. *Pediatr Cardiol* 2014;35:171-9.
 31. Bischoff B, Meinel FG, Del Prete A, Reiser MF, Becker HC. High-pitch coronary CT angiography in dual-source CT during free breathing vs. breath holding in patients with low heart rates. *Eur J Radiol* 2013;82:2217-21.
 32. Long CM, Long SS, Johnson PT, Mahesh M, Fishman EK, Zimmerman SL. Utility of low-dose high-pitch scanning for pediatric cardiac computed tomographic imaging. *J Thorac Imaging* 2015;30:W36-40.
 33. Han BK, Rigby CK, Leipsic J, et al. Computed tomography imaging in patients with congenital heart disease, part 2: technical recommendations: an expert consensus document of the Society of Cardiovascular Computed Tomography (SCCT). *J Cardiovasc Comput Tomogr* 2015;9:493-513.
 34. National Cancer Institute. Radiation Risks and Pediatric Computed Tomography (CT): A Guide for Health Care Providers. 2012. Available at: <http://www.cancer.gov/about-cancer/causes-prevention/risk/radiation/pediatric-ct-scans>. Accessed January 19, 2017.
 35. Taylor AJ, Cerqueira M, Hodgson JM, et al. ACCF/SCCT/ACR/AHA/ASE/ASNC/NASCI/SCAI/SCMR 2010 appropriate use criteria for cardiac computed tomography: a report of the American College of Cardiology Foundation Appropriate Use Criteria Task Force, the Society of Cardiovascular Computed Tomography, the American College of Radiology, the American Heart Association, the American Society of Echocardiography, the American Society of Nuclear Cardiology, the North American Society for Cardiovascular Imaging, the Society for Cardiovascular Angiography and Interventions, and the Society for Cardiovascular Magnetic Resonance. *J Am Coll Cardiol* 2010;56:1864-94.
 36. Angelini P. Novel imaging of coronary artery anomalies to assess their prevalence, the causes of clinical symptoms, and the risk of sudden cardiac death. *Circ Cardiovasc Imaging* 2014;7:747-54.
 37. Rajiah P, Setser RM, Desai MY, Flamm SD, Arruda JL. Utility of free-breathing, whole-heart, three-dimensional magnetic resonance imaging in the assessment of coronary anatomy for congenital heart disease. *Pediatr Cardiol* 2011;32:418-25.
 38. Ripley DP, Saha A, Teis A, et al. The distribution and prognosis of anomalous coronary arteries identified by cardiovascular magnetic resonance: 15 year experience from two tertiary centres. *J Cardiovasc Magn Reson* 2014;16:34.
 39. Feltes TF, Bacha E, Beekman RH 3rd, et al. Indications for cardiac catheterization and intervention in pediatric cardiac disease: a scientific statement from the American Heart Association. *Circulation* 2011;123:2607-52.
 40. Barriales-Villa R, Moris C, Sanmartín JC, Fernandez E, Pajin F, Ruiz Nodar JM. [Anomalous coronary arteries originating in the contralateral sinus of Valsalva: registry of thirteen Spanish hospitals (RACES)]. *Rev Esp Cardiol* 2006;59:620-3.
 41. Angelini P. Sudden death and coronary anomalies: the importance of a detailed description. *Tex Heart Inst J* 2011;38:544-6.
 42. Angelini P, Uribe C, Monge J, Tobis JM, Elayda MA, Willerson JT. Origin of the right coronary artery from the opposite sinus of Valsalva in adults: characterization by intravascular ultrasonography at baseline and after stent angioplasty. *Catheter Cardiovasc Interv* 2015;86:199-208.
 43. Pflederer T, Marwan M, Ropers D, Daniel WG, Achenbach S. CT angiography unmasking catheter-induced spasm as a reason for left main coronary artery stenosis. *J Cardiovasc Comput Tomogr* 2008;2:406-7.
 44. Angelini P, Flamm SD. Newer concepts for imaging anomalous aortic origin of the coronary arteries in adults. *Catheter Cardiovasc Interv* 2007;69:942-54.
 45. Lee SE, Yu CW, Park K, et al. Physiological and clinical relevance of anomalous right coronary artery originating from left sinus of Valsalva in adults. *Heart* 2016;102:114-9.
 46. Brothers J, Carter C, McBride M, Spray T, Paridon S. Anomalous left coronary artery origin from the opposite sinus of Valsalva: evidence of intermittent ischemia. *J Thorac Cardiovasc Surg* 2010;140:e27-9.
 47. Maddoux GL, Goss JE, Ramo BW, et al. Angina and vasospasm at rest in a patient with an anomalous left coronary system. *Cathet Cardiovasc Diagn* 1989;16:95-8.
 48. Kaku B, Shimizu M, Yoshio H, et al. Clinical features of prognosis of Japanese patients with anomalous origin of the coronary artery. *Jpn Circ J* 1996;60:731-41.
 49. Nasis A, Machado C, Cameron JD, Troupis JM, Meredith IT, Seneviratne SK. Anatomic characteristics and outcome of adults with coronary arteries arising from an anomalous location detected with coronary computed tomography angiography. *Int J Cardiovasc Imaging* 2015;31:181-91.
 50. Uebles C, Groebner M, von Ziegler F, et al. Combined anatomical and functional imaging using coronary CT angiography and myocardial perfusion SPECT in symptomatic adults with abnormal origin of a coronary artery. *Int J Cardiovasc Imaging* 2012;28:1763-74.
 51. Mainwaring RD, Reddy VM, Reinhartz O, Petrossian E, Punn R, Hanley FL. Surgical repair of anomalous aortic origin of a coronary artery. *Eur J Cardiothorac Surg* 2014;46:20-6.
 52. Brothers JA, McBride MG, Seliem MA, et al. Evaluation of myocardial ischemia after surgical repair of anomalous aortic origin of a coronary artery in a series of pediatric patients. *J Am Coll Cardiol* 2007;50:2078-82.
 53. Osaki M, McCrindle BW, Van Arsdell G, Dipchand AI. Anomalous origin of a coronary artery from the opposite sinus of Valsalva with an interarterial course: clinical profile and approach to management in the pediatric population. *Pediatr Cardiol* 2008;29:24-30.
 54. Gräni C, Benz DC, Schmied C, et al. Hybrid CCTA/SPECT myocardial perfusion imaging findings in patients with anomalous origin of coronary arteries from the opposite sinus and suspected concomitant coronary artery disease. *J Nucl Cardiol* 2017;24:226-34.
 55. Cheitlin MD, De Castro CM, McAllister HA. Sudden death as a complication of anomalous left coronary origin from the anterior sinus of Valsalva: a not-so-minor congenital anomaly. *Circulation* 1974;50:780-7.
 56. Kragel AH, Roberts WC. Anomalous origin of either the right or left main coronary artery from the aorta with subsequent coursing between aorta and pulmonary trunk: analysis of 32 necropsy cases. *Am J Cardiol* 1988;62:771-7.
 57. Taylor AJ, Rogan KM, Virmani R. Sudden cardiac death associated with isolated congenital coronary artery anomalies. *J Am Coll Cardiol* 1992;20:640-7.
 58. Taylor AJ, Byers JP, Cheitlin MD, Virmani R. Anomalous right or left coronary artery from the

contralateral coronary sinus: "high-risk" abnormalities in the initial coronary artery course and heterogeneous clinical outcomes. *Am Heart J* 1997;133:428-35.

59. Frescura C, Basso C, Thiene G, Corrado D, Pennelli T, Angelini A, Daliento L. Anomalous origin of coronary arteries and risk of sudden death: a study based on an autopsy population of congenital heart disease. *Hum Pathol* 1998;29:689-95.

60. Hill SF, Sheppard MN. Non-atherosclerotic coronary artery disease associated with sudden cardiac death. *Heart* 2010;96:1119-25.

61. Løgstrup BB, Buhl J, Nielsen AD, Smerup MH, Norgaard BL, Kristensen LD. Which exercise test to use for chest pain from an anomalous coronary artery. *Congenit Heart Dis* 2014;9:E6-10.

62. Basso C, Maron BJ, Corrado D, Thiene G. Clinical profile of congenital coronary artery anomalies with origin from the wrong aortic sinus leading to sudden death in young competitive athletes. *J Am Coll Cardiol* 2000;35:1493-501.

63. Maron BJ, Levine BD, Washington RL, Baggish AL, Kovacs RJ, Maron MS. Eligibility and disqualification recommendations for competitive athletes with cardiovascular abnormalities: Task Force 2: Preparticipation Screening for Cardiovascular Disease in Competitive Athletes: a scientific statement from the American Heart Association and American College of Cardiology. *J Am Coll Cardiol* 2015;66:2356-61.

64. Maron BJ, Friedman RA, Kligfield P, et al. Assessment of the 12-lead electrocardiogram as a screening test for detection of cardiovascular disease in healthy general populations of young people (12-25 years of age): a scientific statement from the American Heart Association and the American College of Cardiology. *J Am Coll Cardiol* 2014;64:1479-514.

65. Madsen NL, Drezner JA, Salerno JC. The preparticipation physical evaluation: an analysis of clinical practice. *Clin J Sport Med* 2014;24:142-9.

66. Hainline B, Drezner JA, Baggish A, et al. Interassociation consensus statement on cardiovascular care of college student-athletes. *J Am Coll Cardiol* 2016;67:2981-95.

67. Opolski MP, Pregowski J, Kruk M, et al. Prevalence and characteristics of coronary anomalies originating from the opposite sinus of Valsalva in 8,522 patients referred for coronary computed tomography angiography. *Am J Cardiol* 2013;111:1361-7.

68. Nguyen AL, Haas F, Evens J, Breur JM. Sudden cardiac death after repair of anomalous origin of left coronary artery from right sinus of Valsalva with an interarterial course: case report and review of the literature. *Neth Heart J* 2012;20:463-71.

69. Liberthson RR. Management implications for anomalous aortic origin of coronary arteries. *J Am Coll Cardiol* 2015;8:1250-1.

70. Liberthson R. Congenital anomalies of the coronary arteries. In: Gatzoulis MA, Webb GD, Daubney PEF, editors. *Diagnosis and Management of Adult Congenital Heart Disease*. Edinburgh, UK: Churchill-Livingstone, 2003:425-31.

71. Hillis LD, Smith PK, Anderson JL, et al. 2011 ACCF/AHA guideline for coronary artery bypass graft surgery: a report of the American College of Cardiology Foundation/American Heart Association Task Force on Practice Guidelines: developed in collaboration with the American Association for Thoracic Surgery, Society of Cardiovascular Anesthesiologists, and Society of Thoracic Surgeons. *J Am Coll Cardiol* 2011;58:e123-210.

72. Van Hare GF, Ackerman MJ, Evangelista JA, et al. Eligibility and disqualification recommendations for competitive athletes with cardiovascular abnormalities: Task Force 4: Congenital Heart Disease: a scientific statement from the American Heart Association and American College of Cardiology. *J Am Coll Cardiol* 2015;66:2372-84.

73. Poynter JA, Bondarenko I, Austin EH, et al., for the Congenital Heart Surgeons' Society AAOCA Working Group. Repair of anomalous aortic origin of a coronary artery in 113 patients: a Congenital Heart Surgeons' Society report. *World J Pediatr Congenit Heart Surg* 2014;5:507-14.

74. Brothers JA, Gaynor JW, Jacobs JP, Poynter JA, Jacobs ML. The Congenital Heart Surgeons' Society Registry of Anomalous Aortic Origin of a Coronary Artery: an update. *Cardiol Young* 2015;25:1567-71.

75. Jacobs JP, Pasquali SK, Austin E, et al. Linking the congenital heart surgery databases of the Society of Thoracic Surgeons and the Congenital Heart Surgeons' Society: part 2—lessons learned and implications. *World J Pediatr Congenit Heart Surg* 2014;5:272-82.

76. Aubry P, Halna Du Fretay X, Dupouy P, et al., for the ANOCOR investigators. Isolated proximal anomalous connections of the coronary arteries: a prospective observational cohort study of more than 450 patients (ANOCOR study). *Arch Cardiovasc Dis* 2014;107:501 (abstr).

77. Aubry P, Halna Du Fretay X, Dupouy P, et al., for the ANOCOR Investigators. P6415: Anomalous connections of the coronary arteries: a prospective observational cohort of 472 adults: the ANOCOR Registry. *Eur Heart J* 2015;36:1138 (abstr).

78. Mitka M. US registry for sudden death in the young launched by the NIH and CDC. *JAMA* 2013;310:2495.

79. Vetter VL, Covington TM, Dugan NP, et al. Cardiovascular deaths in children: general overview from the National Center for the Review and Prevention of Child Deaths. *Am Heart J* 2015;169:426-37.e23.

80. Angelini P, Villason S, Chan AV Jr., et al. Normal and anomalous coronary arteries in humans. In: Angelini P, editor. *Coronary Anomalies: A Comprehensive Approach*. Philadelphia, PA: Lippincott Williams & Wilkins, 1999:27-150.

81. Wren C, O'Sullivan JJ, Wright C. Sudden death in children and adolescents. *Heart* 2000;83:410-3.

82. Eckart RE, Scoville SL, Campbell CL, et al. Sudden death in young adults: a 25-year review of autopsies in military recruits. *Ann Intern Med* 2004;141:829-34.

83. Corrado D, Basso C, Pavei A, Michieli P, Schiavon M, Thiene G. Trends in sudden

cardiovascular death in young competitive athletes after implementation of a preparticipation screening program. *JAMA* 2006;296:1593-601.

84. Redelmeier DA, Greenwald JA. Competing risks of mortality with marathons: retrospective analysis. *BMJ* 2007;335:1275-7.

85. Maron BJ, Doerer JJ, Haas TS, Tierney DM, Mueller FO. Sudden deaths in young competitive athletes: analysis of 1866 deaths in the United States, 1980-2006. *Circulation* 2009;119:1085-92.

86. Chugh SS, Reinier K, Balaji S, et al. Population-based analysis of sudden death in children: the Oregon Sudden Unexpected Death Study. *Heart Rhythm* 2009;6:1618-22.

87. Harris KM, Henry JT, Rohman E, Haas TS, Maron BJ. Sudden death during the triathlon. *JAMA* 2010;303:1255-7.

88. Harmon KG, Asif IM, Klossner D, Drezner JA. Incidence of sudden cardiac death in National Collegiate Athletic Association athletes. *Circulation* 2011;123:1594-600.

89. Peñalver JM, Mosca RS, Weitz D, Phoon CK. Anomalous aortic origin of coronary arteries from the opposite sinus: a critical appraisal of risk. *BMC Cardiovasc Disord* 2012;12:83.

90. Lytrivi ID, Wong AH, Ko HH, et al. Echocardiographic diagnosis of clinically silent congenital coronary artery anomalies. *Int J Cardiol* 2008;126:386-93.

91. Krasuski RA, Magyar D, Hart S, et al. Long-term outcome and impact of surgery on adults with coronary arteries originating from the opposite coronary cusp. *Circulation* 2011;123:154-62.

92. Lee HJ, Hong YJ, Kim HY, et al. Anomalous origin of the right coronary artery from the left coronary sinus with an interarterial course: subtypes and clinical importance. *Radiology* 2012;262:101-8.

93. Davies JE, Burkhart HM, Dearani JA, et al. Surgical management of anomalous aortic origin of a coronary artery. *Ann Thorac Surg* 2009;88:844-7; discussion 847-8.

94. Frommelt PC, Sheridan DC, Berger S, Frommelt MA, Tweddell JS. Ten-year experience with surgical unroofing of anomalous aortic origin of a coronary artery from the opposite sinus with an interarterial course. *J Thorac Cardiovasc Surg* 2011;142:1046-51.

95. Mumtaz MA, Lorber RE, Arruda J, Petterson GB, Mavroudis C. Surgery for anomalous aortic origin of the coronary artery. *Ann Thorac Surg* 2011;91:811-4; discussion 814-5.

96. Kaushal S, Backer CL, Popescu AR, et al. Intramural coronary length correlates with symptoms in patients with anomalous aortic origin of the coronary artery. *Ann Thorac Surg* 2011;92:986-91; discussion 991-2.

97. Wittlieb-Weber CA, Paridon SM, Gaynor JW, Spray TL, Weber DR, Brothers JA. Medium-term outcome after anomalous aortic origin of a coronary artery repair in a pediatric cohort. *J Thorac Cardiovasc Surg* 2014;147:1580-6.

98. Sharma V, Burkhart HM, Dearani JA, et al. Surgical unroofing of anomalous aortic origin of a

coronary artery: a single-center experience. *Ann Thorac Surg* 2014;98:941-5.

99. Feins EN, DeFaria Yeh D, Bhatt AB, et al. Anomalous aortic origin of a coronary artery: surgical repair with anatomic- and function-based follow-up. *Ann Thorac Surg* 2016;101:169-75; discussion 175-6.

100. Moustafa SE, Zehr K, Mookadam M, Lorenz EC, Mookadam F. Anomalous interarterial

left coronary artery: an evidence based systematic overview. *Int J Cardiol* 2008;126:13-20.

101. Levine BD, Baggish AL, Kovacs RJ, Link MS, Maron MS, Mitchell JH. Eligibility and disqualification recommendations for competitive athletes with cardiovascular abnormalities: Task Force 1: Classification of Sports: Dynamic, Static, and Impact: a scientific statement from the American Heart Association and American College of Cardiology. *J Am Coll Cardiol* 2015;66:2350-5.

KEY WORDS anomalous coronary artery, interarterial, management, outcomes, prevalence, sudden cardiac death

APPENDIX For supplemental material as well as a figure and tables, please see the online version of this article.