








CONTEMPORARY REVIEW

Therapeutic Management of Anomalous Coronary Arteries Originating From the Opposite Sinus of Valsalva: Current Evidence, Proposed Approach, and the Unknowing

Marius Reto Bigler , MD, PhD; Alexander Kadner , MD; Lorenz Räber , MD, PhD; Afreed Ashraf, BMed; Stephan Windecker , MD; Matthias Siepe , MD; Massimo Antonio Padalino , MD, PhD; Christoph Gräni , MD, PhD

ABSTRACT: Anomalous coronary arteries originating from the opposite sinus of Valsalva (ACAOS) are a challenge because of their various anatomic and clinical presentation. Although the prevalence is low, the absolute numbers of detected ACAOS are increasing because of the growing use of noninvasive anatomical imaging for ruling out coronary artery disease. As evidence-based guidelines are lacking, treating physicians are left in uncertainty for the optimal management of such patients. The sole presence of ACAOS does not justify surgical correction, and therefore a thorough anatomic and hemodynamic assessment is warranted. Invasive and noninvasive multimodality imaging provides information to the clinical question whether the presence of ACAOS is an innocent coincidental finding, is responsible for the patient's symptoms, or even might be a risk for sudden cardiac death. Based on recent clinical data, focusing on the pathophysiology of patients with ACAOS, myocardial ischemia is dependent on both the extent of fixed and dynamic components, represented by anatomic high-risk features. These varying combinations should be considered individually in the decision making for the different therapeutic options. This state-of-the-art review focuses on the advantages and limitations of the common contemporary surgical, interventional, and medical therapy with regard to the anatomy and pathophysiology of ACAOS. Further, we propose a therapeutic management algorithm based on current evidence on multimodality invasive and noninvasive imaging findings and highlight remaining gaps of knowledge.

Key Words: ACAOS ■ anomalous coronary artery originating from the opposite sinus of Valsalva ■ PCI ■ coronary unroofing
■ L-ACAOS ■ R-ACAOS

According to the US and European guidelines with the growing use of recommended noninvasive imaging for the evaluation of coronary artery disease (CAD) in chronic coronary syndromes,¹ an increase in absolute number of newly detected coronary artery anomalies is expected.^{2,3} Of particular interest are anomalous coronary arteries originating from the opposite sinus of Valsalva (ACAOS). There exist different clinical presentations and anatomic variants of

ACAOS. Anomalous courses of the ectopic proximal anomalous coronary artery include prepulmonic (anterior of the pulmonary artery), intraseptal (also called subpulmonic course, with a deep course under the pulmonary artery), retroaortic (behind the aorta), and interarterial (between the great vessels, ie, aorta and pulmonary artery).⁴ Most of these variants are considered benign and coincidental findings with no hemodynamic relevance and thus not related to cardiac

Correspondence to: Christoph Gräni, MD, PhD, FESC, FACC, FSCCT, FSCMR, Department of Cardiology University Hospital Bern, Freiburgstrasse 18, 3010 Bern, Switzerland. Email: christoph.graeni@insel.ch

For Sources of Funding and Disclosures, see page 16.

© 2022 The Authors. Published on behalf of the American Heart Association, Inc., by Wiley. This is an open access article under the terms of the [Creative Commons Attribution-NonCommercial](https://creativecommons.org/licenses/by-nc/4.0/) License, which permits use, distribution and reproduction in any medium, provided the original work is properly cited and is not used for commercial purposes.

JAHA is available at: www.ahajournals.org/journal/jaha

Nonstandard Abbreviations and Acronyms

ACAOS	anomalous coronary artery originating from the opposite sinus of Valsalva
FFR	fractional flow reserve
IVUS	intravascular ultrasound
L-ACAOS	left anomalous coronary artery originating from the opposite sinus of Valsalva
R-ACAOS	right anomalous coronary artery originating from the opposite sinus of Valsalva
SCD	sudden cardiac death

symptoms (ie, prepulmonic, subpulmonic, retroaortic, intraseptal). Conversely, the ACAOS variant with an interarterial course, that is, with the anomalous vessel running between the great arteries, is the foremost potential hemodynamical relevant anomaly. These interarterial variants are historically referred to as “malignant variants” based on the anticipated higher risk for myocardial ischemia and sudden cardiac death (SCD), especially affecting young adults during strenuous physical activity.^{5–10} However, these risk estimations derive from autopsy studies and do not reflect the absolute risk of SCD in people living with ACAOS,¹¹ which is considered to be rather low.^{12,13} In the general population, ACAOS with an interarterial course prevalence is reported to be low (<0.5%), with a more frequent occurrence of right ACAOS (R-ACAOS, 0.23%) compared with left coronary ACAOS (L-ACAOS, 0.03%).^{3,14} Several management options for ACAOS are proposed,^{15,16} but they are still under debate, as the exact pathophysiology is not completely understood. Furthermore, the level of evidence supporting the US and European guidelines about diagnostic and therapeutic approaches in patients with these anomalies is limited,^{17–21} and treating physicians are often left in uncertainty about how they should counsel their patients.¹⁵ As the sole presence of ACAOS does not justify surgical repair in all patients, a comprehensive diagnostic workup of these anomalies combining noninvasive and invasive assessment to evaluate the anatomy as well as the hemodynamic relevance under stress conditions is warranted.^{15,16,22} The pathophysiology of myocardial ischemia in ACAOS is not only represented by a fixed stenosis (as known from plaques in CAD) but also by a dynamic component. Both components are represented by different anatomic high-risk features and have to be considered when assessing such patients.²³ As different combinations and extent of anatomic high-risk features can result in hemodynamic significance, treatment options have to be optimally

selected to correct all components and to eliminate the hemodynamic relevance of the anomalous coronary artery. This state-of-the-art review focuses on the advantages and limitations of the common contemporary surgical, interventional, and medical therapy with regard to the anatomy and pathophysiology of ACAOS. Further, we propose a therapeutic management algorithm based on current evidence on multimodality invasive and noninvasive imaging findings and highlight remaining gaps of knowledge.

PATHOPHYSIOLOGICAL MECHANISMS OF ISCHEMIA IN ACAOS

Despite growing understanding of the pathophysiology of ACAOS, the underlying mechanisms of ischemia remain ambiguous because of the highly variable extent of the different anatomic high-risk features.²² The interarterial course was historically considered to be main driver of ischemia, assuming a scissor-like interruption of the coronary blood flow, especially during exertion, as a consequence of the close proximity of the anomalous segment to the aorta and pulmonary artery.⁵ However, considering the pressure condition in the respective circulatory systems, it is unlikely that the low-pressure pulmonary artery would develop substantial counterforce to occlude the higher-pressure anomalous coronary artery. On the contrary, at the site of closest aortopulmonary proximity, the anomalous segment frequently runs inside the aortic wall with associated other anatomic high-risk features.^{6,24,25} Therefore, the interarterial course may rather act as a surrogate for the anatomic high-risk features such as the slitlike ostium, the acute take-off angle, the proximal narrowing (also referred to as hypoplasia) with elliptic vessel shape, and, most importantly, the intramural course (ie, course within the tunica media of the aortic wall).^{25–36} In the 2-tier concept, hemodynamic relevance of the fixed components is featured by the slitlike ostium and proximal narrowing, while the dynamic component is represented by the acute take-off angle, elliptic vessel shape, and, most importantly, the intramural course. Elements of the fixed component correspond best to the concept of obstructive coronary stenosis known from CAD, that is, flow restrictions based on the static reduction of the cross-sectional area. Accordingly, assessment can be performed similarly to patients with CAD, including determination of percentage of cross-sectional area stenosis of the anomalous in relation to the unobstructed, distal reference segment,³⁷ or measurement of the pressure gradient over the anomalous segment, that is, fractional flow reserve (FFR) or noninvasive ischemia testing using adenosine as a pharmacologic vasodilator.³⁸ Revascularization may then be

considered in case of a reduction of the cross-sectional area $>50\%$ in the intravascular ultrasound (IVUS)³⁷ or an FFR <0.80 or the presence of noninvasive assessed ischemia.³⁸ Of note, FFR cutoff values are adopted from the experience in CAD and have not been validated in ACAOS. Conversely, anatomic features of the dynamic component (which may represent the main driver for ischemia in ACAOS) gain hemodynamic relevance only during exercise and elevation of stroke volume, blood pressure, and heart rate. Of note, pharmacologic vasodilatation cannot assess the dynamic components, as it requires an increased cardiac output with subsequent augmented vessel wall stress of the aorta.^{24,39–44} These exercise-induced adaptations can provoke a lateral compression sufficient to cause myocardial ischemia (even during diastole). Therefore, physical stress or positive inotrope/positive chronotrope protocols including volume infusion to mimic strenuous exercise are needed to depict ischemia by dynamic compressions. Angelini et al³⁷ illustrated this concept in a study using IVUS under rest and during dobutamine infusion, a beta-sympathomimetic drug that increases heart rate and stroke volume.^{37,39,41} Furthermore, not only the presence but also the extent of the intramural course seems to be relevant. In particular, the peculiar anatomic characteristic of the length related to the width of the intramural segment itself may mostly contribute to the dynamic component and therefore to the pathophysiology of ACAOS. The normal anatomic origin and intraparietal aortic wall course of a coronary artery is characterized by an exit angle, which is approximately equal to 90° (Figure 1A). On the contrary,

when there is an abnormal angulated orifice, the coronary vessel passes obliquely through the aortic wall for a distance (a), which is equal or inferior to the coronary artery's diameter (b), and the exit-angle ranges typically between 45° and 90° (Figure 1B). Finally, in the presence of an abnormal intramural course, the coronary vessel passes obliquely through the aortic wall for a distance (a), which is greater than the coronary artery's diameter (b), and the exit angle is about $>0^\circ$ to 45° (Figure 1C). In this latter case, the length of the intramural tract is greater than the coronary diameter ($a>b$). The latter diagram clarifies that the longer the intramural tract is, the more prone it is to intraparietal compression during acute systolic blood pressure increase, as in strenuous physical effort, which can justify the increased ischemic risk for this anatomic characteristic. Intuitively, the longer the tract is, the higher the risk of prolonged coronary occlusion, but there are currently no data supporting this hypothesis, which could also help predict and stratify the ischemic risk. Several studies have shown that the length of the intramural segment^{25,32,45,46} as well as the extent of the elliptic proximal vessel shape (defined as height/width ratio of >1.3 ⁴⁷) is associated with an increased risk for ischemia. However, in previous studies, none of the anatomic features correlated independently with ischemia.²² Thus, a complex interplay between the different dynamic and fixed components has been suggested. In addition, hemodynamic relevance depends on the supplied myocardial mass⁷ as well as other contributing factors (eg, volume status and type of physical activity).²² Further, several findings suggest an age

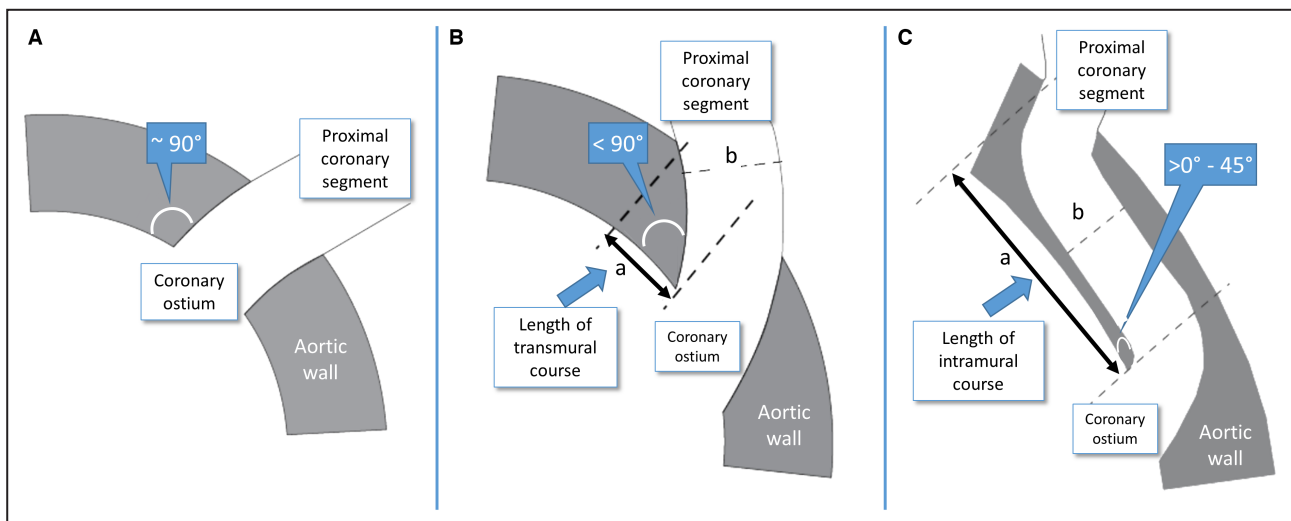


Figure 1. Illustration with variants of proximal coronary artery anatomy.

A, The normal anatomic origin and intraparietal aortic wall course of a coronary artery, and the exit angle is equal to $\approx 90^\circ$. **B**, The abnormal angulated orifice: the coronary vessel passes obliquely through the aortic wall for a distance (a) that is equal or inferior to the coronary artery's diameter (b), and the exit angle is $<90^\circ$. **C**, The abnormal intramural course: the coronary vessel passes obliquely through the aortic wall for a distance (a), which is greater than the coronary artery's diameter (b), and the exit angle is about $>0^\circ$ to 45° . Of note, proximal narrowing exceeds the intramural course in most cases. Hence, juxta-aortic calibers are frequently smaller than the distal reference calibers.

dependence because of a reported decreased risk for SCD beyond the age of 30 years.^{33,35} It has been demonstrated that the midterm outcome in middle-aged individuals with newly diagnosed ACAOS is not statistically different from a matched control cohort without ACAOS irrespective of the anatomic high-risk features.¹³ In this context, the underlying mechanism could be attributable to either selection bias toward low-risk patients with increasing age or a pathophysiologic explanation. It is conceivable from a pathophysiologic point of view, that with increasing age, thickening and increasing stiffness of the aortic wall is associated with a decrease of the distensibility,⁴⁸ and thus, the dynamic component may become less relevant. On the other side, one could argue that with aging the distention of the aorta could even accentuate anatomic high-risk features such as a slitlike ostium or acute take-off angle. Another important point is to consider that in older patients with ACAOS, possible concomitant CAD may step into the front, resulting in myocardial ischemia based solely on CAD^{30,49} or the combination of both the anomalous vessel and atherosclerotic lesions within the same anomalous vessel.⁵⁰

DIAGNOSTIC MANAGEMENT OF ACAOS

Based on the complex pathophysiologic mechanisms of myocardial ischemia in patients with ACAOS, the clinical presentation is heterogeneous.¹⁴ In fact, most patients are asymptomatic; however, encountered symptoms may include angina pectoris, exercise-related or -unrelated chest pain, palpitations, dyspnea, dizziness, syncope, and myocardial infarction as well as SCD.^{6,11,28,37,51–64} Besides acute ischemia-induced arrhythmias, repetitive minor ischemic events with consecutive myocardial fibrosis may serve as a substrate for ventricular tachyarrhythmias and SCD.^{6,65} Consequently, multimodality

diagnostic management of patients with ACAOS should not only imply the detection of anatomic high-risk features and myocardial ischemia of ACAOS but also provide information for possible myocardial fibrosis/scar in suspected cases (Figure 2).^{14,15,30}

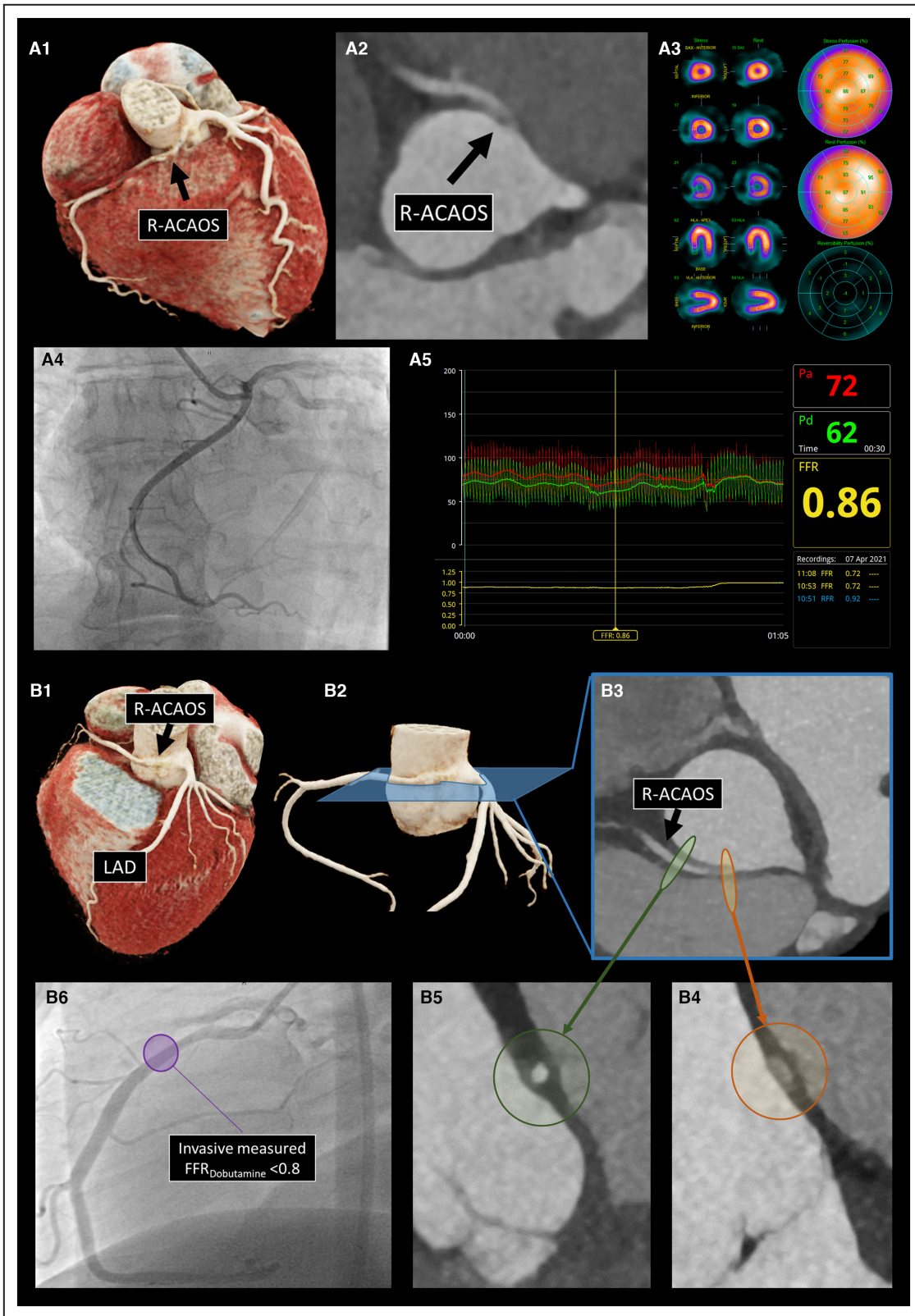
We recently proposed a testing algorithm in individuals who present with stable symptoms or who are asymptomatic with suspected or confirmed ACAOS. The testing algorithm includes anatomic and ischemia testing with the main goal to differentiate hemodynamically relevant ACAOS from innocent coincidental bystanders.²² Of note, in patients with ACAOS presenting in an acute setting (ie, myocardial infarction, troponin leakage) direct revascularization should be aimed.⁶⁵ Based on previous studies showing a reduced risk for potentially serious adverse events with increasing age,^{13,33,35,66} the diagnostic downstream testing recommendations have been adapted to age (below and above 30 years old). One has to be aware that dichotomization of the age 30 years is arbitrary and should not be seen as a stringent recommendation but should rather be seen as a guidance.

Noninvasive Diagnostic Assessment

In the population <30 years of age, and especially in the pediatric population, the initial diagnostic modality should be transthoracic echocardiography by an experienced sonographer. Transthoracic echocardiography enables the imaging of the origin and the proximal course of the coronary arteries noninvasively and without radiation exposure.^{46,67} If ACAOS cannot be ruled out with certainty (eg, low acoustic window quality⁶⁸) or in cases in which ACAOS is confirmed, additional imaging is required to assess and quantify the anatomic high-risk features including the intramural course. Coronary computed tomography angiography (CCTA) or cardiac magnetic resonance (CMR) imaging are ideal anatomic diagnostic modalities in ACAOS, whereas CCTA provides the

Figure 2. Comparison of the diagnostic management in 2 similar cases of R-ACAOS.

A, A 65-year-old woman with atypical chest pain and exertional dyspnea (New York Heart Association class II) since 4 months. Normal electrocardiographic and echocardiographic (LVEF 60%) findings, bicycle exercise testing with exercise-induced dyspnea without ischemic ECG alterations at heart rate (HR) 154/min (99% of maximum HR). **A1** and **A2**, Coronary computed tomography angiography showing absence of coronary artery diseases (CAD), a R-ACAOS with acute take-off angle (18.3°), an intramural course (7.8 mm) and an elliptic vessel shape (ratio 2.8). No slitlike ostium or proximal narrowing could be illustrated. **A3**, Single-photon emission computed tomography with physical stress showing no exercise-induced myocardial ischemia at a HR of 155/min. **A4**, Invasive coronary angiography illustrating both the anomalous and the left coronary artery with one injection (projection: right anterior-oblique 2°, caudal 8°). **A5**, Invasive physiologic assessment with FFR during a dobutamine-volume challenge demonstrating absence of hemodynamic relevance. **B**, A 48-year-old man with fatigue, atypical chest pain, and occasionally dyspnea/palpitations since 6 months. Normal electrocardiographic and echocardiographic (LVEF 60%) findings, bicycle exercise testing without symptoms or ischemic ECG alterations at max. HR of 167/min (97% of maximum HR), **B1** through **B3**, CCTA showing absence of CAD, an R-ACAOS with acute take-off angle (3.9°), an intramural course (14.3 mm), an elliptic vessel shape (ratio 3.4) as well as a slitlike ostium. No relevant proximal narrowing could be illustrated. **B4** and **B5**, Illustration of the oval vessel shape within the intramural course (**B4**) and normalization of the round vessel shape at the distal reference site (**B5**). **B6**, Invasive coronary angiography illustrating both the anomalous and the left coronary artery with 1 injection (projection: left anterior-oblique 84°, caudal 7°) Invasive physiologic assessment with FFR_{Dobutamine} demonstrating hemodynamic relevance of the anomalous course. CAD indicates coronary disease; CCTA, coronary computed tomography angiography; FFR, fractional flow reserve; LVEF, left ventricular ejection fraction; and R-ACAOS, right anomalous coronary artery originating from the opposite sinus of Valsalva.



Downloaded from <http://ahajournals.org> by on October 14, 2022

best noninvasive spatial resolution as well as the possibility to evaluate the full course of the coronary arteries.^{14,15,30} One of the main advantages of CMR is that it inherits the ability to visualize and assess the origin and

the proximal course of the anomalous coronary artery without radiation.⁶⁹⁻⁷¹ Whether CMR may further help to detect patchy myocardial necrosis with regard to SCD prevention in ACAOS is under discussion.⁷² In cases of

ACAOS without anatomic high-risk features (“benign” variants), no further testing is needed. In all other cases, noninvasive and if applicable invasive functional testing is recommended (ie, transthoracic echocardiography, CMR, single photon emission computed tomography or positron emission tomography using physical exercise or dobutamine stimulation).

In the population >30 years of age, direct CCTA is recommended to assess the presence or absence of concomitant CAD.

Invasive Diagnostic Assessment

For decades, invasive coronary angiography has been seen as the anatomic diagnostic gold standard in patients with ACAOS. However, currently state-of-the-art CCTA/CMR is preferred because of its lower costs and the ability to noninvasively provide high-resolution visualization of the anatomic high-risk features, whereas invasive coronary angiography serves rather as an alternative modality in defining the anatomy of ACAOS.²² However, invasive coronary angiography in combination with intravascular imaging such as IVUS or optical coherence tomography still plays an important role in assessing high-risk features. Although optical coherence tomography provides a better spatial resolution, it is limited by a larger probe diameter and requires continuous contrast agent injection during recording. Two limitations especially relevant in ACAOS with a slitlike ostium and high-grade proximal narrowing. Further, IVUS and invasive FFR are the preferred modality to assess functional, dynamic changes under stress conditions.

Stress Protocols in ACAOS

One must be aware that noninvasive functional testing in ACAOS might lead to false-negative results, especially after submaximal stress protocols.⁷³ When choosing a noninvasive functional testing, myocardial perfusion stress positron emission tomography might represent the most sensitive technique, as it allows not only a qualitative but also a quantitative assessment of the coronary flow under stress and resting conditions.⁴⁹ However, probably the most adequate hemodynamic assessment of ACAOS includes an invasive physiologic evaluation under a dobutamine/volume challenge (ie, IVUS/optical coherence tomography and FFR). The protocol aims to reach, if possible, a maximal stress test (ie, 100% of the maximal heart rate, estimated by the formula 220 minus age) by using a dobutamine dose up to 40 µg/kg per body weight per minute as well as steady infusion of saline during the whole procedure (usually >1500 mL to prevent a preload decrease). If target heart rate cannot be achieved, 1 mg of atropine can be added to the ongoing dobutamine infusion. It is important to note that the intubation of the anomalous ostium in combination with advanced diagnostic including FFR

and intravascular imaging requires a high level of expertise and should be performed by ACAOS-experienced interventional cardiologists.⁷⁴ Potential but rare risks include aortic or coronary dissections with consecutive myocardial infarction or stroke. Further, the invasive assessment using a dobutamine challenge is not feasible in every patient and especially poses difficulties in the pediatric population, where invasive imaging frequently requires general anesthesia. In these cases, noninvasive functional imaging might be the preferred approach. Consequently, it is recommended to refer patients with ACAOS to a specialized and experienced tertiary center where coronary artery anomalies are interdisciplinarily managed by cardiac imaging specialists, interventional cardiologists, and heart surgeons.

THERAPY OF PATIENTS WITH ACAOS

Because of the complex pathological mechanisms of myocardial ischemia in patients with ACAOS, a uniform treatment strategy is not applicable. Based on the presence of different anatomic high-risk features, possible concomitant CAD, and functional imaging, an individually tailored therapy is advised (see Table 1). Of note, the pre- and postoperative diagnostic assessment in published trials is heterogeneous, and evidence of ACAOS-related myocardial ischemia exists only in few studies.^{25,52} Because of the limited information on the diagnostic workup, evidence is lacking whether the indication for surgical correction of ACAOS was truly beneficial or whether the operation was performed in hemodynamic nonrelevant anomalies. Consequently, thorough verification of the therapeutic success is not possible on the basis of the existing published data.

Surgical Management

Surgical revascularization is the primary treatment strategy in patients with hemodynamically relevant ACAOS.^{52,75,76} An overview of the most relevant clinical trials with regard to treatment of patients with ACAOS is depicted in Table 2.^{28,37,51-64} Although coronary “unroofing” is the most common surgical procedure reported in the literature,⁷⁶ currently there are no recognized guideline recommendations on surgical techniques (neither in the American Heart Association/American College of Cardiology 2018 guidelines¹⁹ nor in the European Society of Cardiology 2020 guidelines²⁰). Various surgical techniques have been reported, and the most common procedures with their advantages and limitations are outlined below.

Coronary Unroofing/Neo-Ostium Creation

In ACAOS with the presence of an intramural course, coronary unroofing is the preferred surgical revascularization therapy according to a recent study by the

Table 1. Overview of the Therapeutic Possibilities

	Coronary unroofing/ Neo-ostium	Translocation/ Reimplantation	Coronary ostioplasty	CABG	Pulmonary artery translocation	PCI	Conservative management
Anatomic high-risk features to be addressed							
Fixed components							
Slitlike ostium	+++	+	+++	++	-	+	-
Proximal narrowing	++	++	+++	++	-	+	-
Dynamic components							
Anatomic high-risk features to be addressed							
Dynamic components							
Acute take-off angle	++	+++	++	++	-	-	-
Intramural course with lateral compression	+++	+++	+++	++	-	++	+
Advantages							
	Largest clinical evidence	Applicable in different anatomic situations	True anatomic repair	Large technical experience from CAD	Low procedural risk	Low-invasive	No surgery/good option in low-risk or asymptomatic middle- aged/older population
Limitations							
	Risk of aortic regurgitation and remaining stenosis, length of the intramural course	Challenging procedure requiring coronary mobilization; circumferential anastomosis	Challenging procedure, unclear long-term outcome of patch plastic	Competitive flow through anomalous native segment causing graft failure	Does not address important anatomical high-risk features	Unclear long-term stent patency/possible restenosis and outcome	Negative emotional and health aspects

CABG indicates coronary artery bypass grafting; CAD, coronary artery disease; and PCI, percutaneous coronary intervention; conservative management=medical therapy (eg, beta-blocker) and sports restrictions.

Table 2. Overview of the Most Relevant Clinical Trials With Regard to Treatment of Patients With ACAOS

Authors	Journal	Year of publication	Population	Symptoms	Diagnostic assessment	Therapeutic management	Outcome	Limitations
Jegatheeswaran et al ⁵²	<i>J Thorac Cardiovasc Surg.</i>	2020	n=682; median age, 12.9 y R-ACAOs 74% L-ACAOs 24%	Not reported	Preoperative ischemia testing 41%, 64/395 positive Cardiac imaging unclear	Surgery 24% 1. Unroofing 87% 2. Osteoplasty 6% 3. PA translocation 6% 4. Reimplantation 6% 5. Neo-ostium 3% 6. CABG 1% (multiple techniques possible per patient) Conservative 76%	3% coronary-related reoperations 1% death at 30 d Median FU, 2.8 y Postoperative ischemia testing 48%, 26/395 positive	Low rate of myocardial ischemia testing, No information on preoperative cardiac imaging
Mery et al ⁵³	<i>J Thorac Cardiovasc Surg.</i>	2018	n=162; median age, 14 y R-ACAOs 72% L-ACAOs 15%	Data only available for surgical patients None 27% Typical AP 36% Atypical AP 36% Dyspnea 7% Palpitations 9% Syncope 21% SCA 7%	Echocardiography CCTA Stress nuclear perfusion imaging	Surgery 38% 1. Unroofing 80% 2. Translocation 16% 3. Osteoplasty 2% 4. Side-side-anastomosis 2% Conservative 62%	3-month FU, 95% 17% abnormal nuclear perfusion imaging, 12% with mild ostial stenosis in the CCTA Median FU, 2 y 91% asymptomatic, 9% nonspecific chest pain	Short follow-up, broad indication for surgery (L-ACAOs, symptoms suggestive of ischemia, positive functional test, high-risk anatomy)
Padalino et al ⁵⁴	<i>Eur J Cardiothorac Surg.</i>	2019	n=156; median age, 39.5 y R-ACAOs 68% L-ACAOs 22%	None 13% Typical AP 27% Dyspnea 6% Palpitations 5% Syncope 9% SCA 14%	Echocardiography 96% CCTA 72% Functional testing occasionally	Unroofing 56% Reimplantation 19% CABG 15% (older patients) Osteoplasty 6% PA translocation 1%	Operative mortality 1.3%, 9% with major postoperative complications Median FU, 2 y; 5 coronary-related AE, 14% with persistent symptoms (undefined chest pain)	No exact anatomic description, few functional assessment
Fabozzo et al ⁵⁵	<i>Semin Thorac Cardiovasc Surg.</i>	2016	n=155; median age, 8.5 y R-ACAOs 82% L-ACAOs 18%	None 48% Typical AP 14% Atypical AP 10% Syncope 10% SCA 3% Myocardial infarction 1%	Echocardiography 90% CAG 20% CMR or CT 57% Stress echocardiography 22% SPECT 19% Total positive stress test=7%	Surgery 46% 1. Unroofing 86% 2. Reimplantation 11% 3. PA translocation 1% Conservative 54%	Major perioperative complications 4% Median FU, 1.9 y Stress-testing 53%, no evidence of ischemia on perfusion imaging	Low rate of confirmed myocardial ischemia
Poynter et al ⁵⁶	<i>World J Pediatr Congenit Heart Surg.</i>	2014	n=113; median age, 12.6y R-ACAOs 69% L-ACAOs 29%	Not reported	Not reported	Unroofing 88% Reimplantation 10% PA translocation 6% Osteoplasty 3% CABG 2%	Not reported	No information on diagnostic assessment and outcome

(Continued)

Table 2. Continued

Authors	Journal	Year of publication	Population	Symptoms	Diagnostic assessment	Therapeutic management	Outcome	Limitations
Courand et al ⁵⁷	<i>Int J Cardiol.</i>	2021	n=100, mean age 24±19y R-ACAOs 60% L-ACAOs 27%	None 25% Typical AP 28% Atypical AP 8% Dyspnea 4% Syncope 11% SCA/myocardial infarction/pulmonary edema 12%	Echocardiography 65% CCTA 35% Dobutamine stress echocardiography 0/1 positive SPECT 3/9 positive Stress ECG 3/12 positive	Surgery 61% 1. Reimplantation 98% 2. Unroofing 2% Medical therapy 39%	Mean FU, 4.9±5.3 y No death for any of the groups, no recurrence of symptoms for the operated patients	No exact anatomic description, few functional assessment
Mainwaring et al ⁵⁸	<i>Eur J Cardiothorac Surg.</i>	2014	n=76; median age, 15 y R-ACAOs 62% L-ACAOs 35%	None 21% Typical AP 38% Atypical AP 10% Syncope 16% Dyspnea 4%	Echocardiography CCTA	Unroofing 72% Reimplantation 9% PA translocation 18%	No operative mortality, no reoperation Mean FU, 6 y No new evidence for myocardial ischemia	No functional assessment
Sharma et al ⁵⁹	<i>Ann Thorac Surg.</i>	2014	n=75; mean age, 40±20 y R-ACAOs 92% L-ACAOs 8%	None=28% Chest pain 68% Syncope 20% SCA 3% Myocardial infarction 3%	CCTA CGA Stress test 53%, 20/40 positive	Unroofing 100% 3% additional CABG on the anomalous vessel	Mean FU, 1.56±0.2 y, no reported symptoms, negative stress and anatomic FU test	Low rate of confirmed myocardial ischemia
Angelini et al ⁵⁷	<i>Catheter Cardiovasc Interv.</i>	2015	n=67; mean age, 48±12 y R-ACAOs 100%	None 12% Typical AP 66% Atypical AP 21% Dyspnea 54% Syncope 22%	CCTA (36%) CAG with IVUS and dobutamine-volume challenge (100%)	PCI (62%) Surgical (4%) Medical (33%)	Mean FU, 5.0±2.9 y 2/23 positive nuclear study; 4/10 CAG with in-stent restenosis	Low rate of repeated invasive assessment
Sachdeva et al ⁶⁰	<i>J Thorac Cardiovasc Surg.</i>	2017	n=63; median age, 13 y R-ACAOs 79% L-ACAOs 21%	None 46% Typical AP 19% Atypical AP 21% Syncope 3% Palpitations 2% SCA 6%	Echocardiography 95% CCTA 19% CAG 13% CMR 22% Stress CMR 6% (0/4 positive) Stress ECG 43% (3/27 positive) Stress echocardiography 10% (0/10 positive)	Unroofing 100%	No surgical mortality, no coronary reinterventions Median FU, 3.1 y Stress testing without evidence for reversible ischemia; 3 sudden SCA (1/3 death)	Low rate of confirmed myocardial ischemia No exact anatomic description

(Continued)

Table 2. Continued

Authors	Journal	Year of publication	Population	Symptoms	Diagnostic assessment	Therapeutic management	Outcome	Limitations
Kaku et al ⁶¹	<i>Jpn Circ J.</i>	1996	n=56; mean age, 56±12 R-ACAOs 79% L-ACAOs 0%	None 13% Typical AP 40% Atypical AP 38% Dyspnea 2% Palpitations 4% Syncope 2%	CAG with ergovine (2/7 positive) Stress ECG (16/33 positive) SPECT (4/9%)	Exercise restriction (4/44) Medical treatment (13/44) Both (12/44) None (15/44)	Mean FU, 5.6±4.2 y (n=44) No deaths attributed to the anomaly	Low rate of confirmed myocardial ischemia No imaging of the anatomic high-risk features
Kara et al ⁵¹	<i>Eur J Cardiothorac Surg.</i>	2021	n=39; median age, 14 y R-ACAOs 72% L-ACAOs 28%	None 20% Chest pain 56% Dizziness 33% Dyspnea 15% Syncope 13% Cardiac arrest 5% (>1 possible)	Stress-test (unspecified) 4/32 positive	Coronary unroofing 77%, (37% with additional PA translocation) PA translocation 8% CABG 7% Reimplantation 5%	Median FU, 4 y FU CCTA after 3–6mo, 3 revascularization procedures	Low rate of confirmed myocardial ischemia
Davies et al ⁶²	<i>Ann Thorac Surg.</i>	2009	n=36; mean age, 44±16 y R-ACAOs 58% L-ACAOs 36%	None 29% Chest pain 56% Dyspnea 19% Syncope 6%	Stress test (unspecified) 9/21 positive	Coronary unroofing 61% CABG 39%	Mean FU, 1.1±2.8 y; 1 patient with recurrent symptoms (CABG; patent flow)	No exact anatomic description, few functional assessment
Feins et al ⁶²	<i>Ann Thorac Surg.</i>	2016	n=31; mean age, 43±3y R-ACAOs 77% L-ACAOs 19%	None 6% Chest pain 38% Typical AP 27% Dyspnea 19% Palpitations 6% Syncope 6% SCA 6% Myocardial infarction 6%	Not reported	Unroofing 68% Translocation 19% CABG 13%	Mean FU, 3.8±0.8 y 42% FU CCTA, 1/13 mild stenosis 55% functional testing, 2/17 positive (1x CABG, 1x unroofing)	No information on preoperative diagnostic assessment
Mumtaz et al ⁶³	<i>Ann Thorac Surg.</i>	2011	n=22; median age, 15 y R-ACAOs 68% L-ACAOs 32%	None 5% Typical AP 68% Syncope 23% Myocardial infarction 5%	Echocardiography (100%) CCTA (77%) CMR 5% Nuclear study 27%, half positive	Coronary unroofing	Mean FU, 1.4 y; 5% still symptomatic without evidence of ischemia	No exact anatomic description, few functional assessment
Ibraheem et al ⁶⁴	<i>J Card Surg.</i>	2019	n=16; mean age, 35±5y R-ACAOs 100%	Typical AP 31% Atypical AP 69% Syncope 38% Palpitations 50% (>1 possible)	CAG CCTA Dobutamine stress echocardiography 7/16 positive SPECT 4/16 positive	CABG 100% including ligation of the RCA in 94%	One in-hospital death 5-y FU, 13/16 patent grafts (CCTA)	Low rate of confirmed myocardial ischemia

AE indicates adverse event; ACAOS, anomalous coronary arteries originating from the opposite sinus of Valsalva; AP, angina pectoris; CAG, coronary angiography; CABG, coronary artery bypass grafting; CCTA, coronary computed tomography angiography; CMR, cardiovascular magnetic resonance imaging; FU, follow-up; IVUS, intravascular ultrasound; L-ACAOs, left anomalous coronary arteries originating from the opposite sinus of Valsalva; ns, statistically nonsignificant; PA, pulmonary artery; R-ACAOs, right anomalous coronary arteries originating from the opposite sinus of Valsalva; SCA, sudden cardiac arrest; and SPECT, single-photon emission computed tomography.

Congenital Heart Surgeons Society.⁵² After exploration and confirmation of the intramural course using a coronary probe, the common wall with the aorta is sharply excised or incised over the probe along its entire intramural course proximal to the site where it emerges from the aortic wall.^{77,78} In addition, tacking sutures are placed to ensure intimal continuity and prevent dissection. Further, the combination with an “unroofing” technique by augmenting the antiaortic side of the coronary artery with a longitudinal patch has been described.⁷⁹ A neo-ostium is formed in the “correct” sinus of Valsalva, usually with an enlargement of the ostium (Figure 3A), and hence, the unroofing procedure includes a component of coronary ostioplasty.⁷⁶ The therapeutic procedure of coronary unroofing directly addresses the anatomic high-risk feature slitlike ostium as well as the intramural course with its elliptic vessel shape. However, acute take-off angle is often not completely corrected,⁷⁶ and proximal narrowing frequently exceeds the intramural segment. Thus, caliber of the anomalous vessel returns to its normal, distal reference parameter several millimeters distal to the aortic wall. Therefore, a remaining coronary stenosis between the unroofed segment and the distal coronary artery is possible.⁸⁰

Based on the largest body of evidence for a surgical procedure in ACAOS,¹ coronary unroofing should be applied in situations with a long course (ie, up to the appropriate cusp) without contact with the commissure. However, other important anatomic features may limit its ubiquitous application. Especially in cases where the anomalous vessel traverses below or next to the commissure, an unroofing along the entire intramural course could impair the suspension of the aortic valve. In these anatomic variants, the treatment should be characterized by either detaching the commissure or performing a commissural resuspension⁸¹ or aortocoronary window, that is, unroofing before and after the commissure while leaving the commissure intact.^{56,67,83,88} In fact, there is evidence that commissural manipulation (defined as takedown or resuspension of the commissure) is associated with a higher risk of postoperative aortic regurgitation.⁵² Formation of a neo-ostium at the location where the anomalous vessel emerges from the aortic wall without concomitant unroofing has been described as a valuable alternative.^{58,83}

Further, success of the unroofing procedure depends on the length of the intramural course. Mery et al⁵³ demonstrated that patients with a long intramural segment benefit the most, whereas a short intramural segment limits the success of the unroofing technique. This is particularly true in cases where the anomalous vessel remains within the incorrect sinus and courses through a thickened commissure or pillar (ie, the aortic wall segment above the commissure^{76, 82}). Although in

such variants, unroofing may increase the size of the ostium, it does not address compression of the pillar or proximal narrowing. Hence, significant flow restriction may persist as described in the study by Mery et al,⁵³ where this was the case in 4 of 5 cases as documented in postoperative CCTA. Furthermore, a short intramural course is often associated with an insufficient correction of the acute take-off angle after unroofing and thus persistent hampered coronary flow patterns.⁸⁶

Coronary Translocation/Reimplantation

Coronary translocation or reimplantation of the anomalous coronary artery in the appropriate sinus of Valsalva is a method often described in patients with either a short or absent intramural course, where the unroofing technique is limited.^{11,54,57,62,90} Further, reimplantation has been applied in the situation of rare ACAOS variants with intraseptal or intraconal course in combination with a supra-arterial myotomy of the aberrant segment.^{91–93} Coronary translocation starts with careful mobilization of the proximal coronary artery in the epicardial fat, followed by a transection with aortic button and reimplantation in the “correct” sinus of Valsalva using an aortic punch or a medial trap-door technique.^{62,87} Afterwards, the ostium’s original location is closed with a small prosthetic patch⁷⁶ (Figure 3B). Alternatively, translocation of the anomalous coronary artery by transecting it just as it emerges from the aortic wall has been described. The proximal stub is then oversewn and the coronary artery reimplanted by an end-to-site anastomosis.^{62,94,95} Similar to coronary unroofing, coronary translocation corrects the anomalous intramural course. However, a slitlike ostium and proximal narrowing are often not corrected, requiring an additional procedure, that is, coronary ostioplasty.⁹⁶ In general, coronary translocation is a challenging procedure and involves extensive dissection and manipulation of the artery, both associated with complication as neo-ostial obstruction, kinking, and flow disruption.^{76,85,95,96} In addition, the long-term effect of a circumferential anastomosis, especially in young patients, is unknown.⁵³

Coronary Ostioplasty

Coronary ostioplasty (ie, “anatomic surgical repair”) refers to a surgical technique with complete reconstruction of the anomalous coronary ostium.^{76,96} This procedure (Figure 3C) starts with transection of the aortic wall followed by an incision from the cut edge of the aorta into the ostium of the anomalous coronary artery and extended into the anomalous vessel. Finally, a triangular patch (usually pericardium) is sutured into this incision, resulting in the creation of a neo-ostium as well as an enlarged proximal segment.⁹⁷ By creating

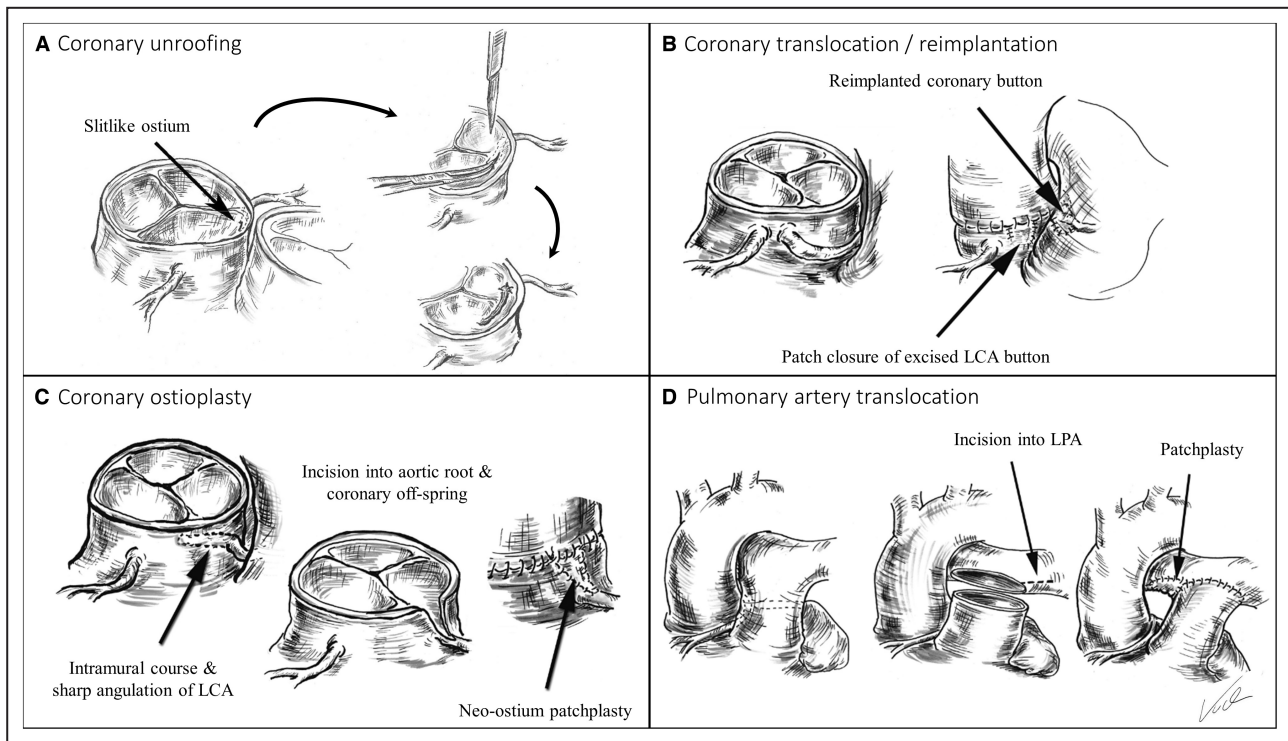


Figure 3. Illustration of the different surgical procedures.

A, Coronary unroofing. Exploration of the intramural course using a coronary probe is followed by excision/incision of the common wall with the aorta over the probe along its entire intramural course proximal to the site where it emerges from the aortic wall. Then, a neo-ostium is formed. **B**, Coronary translocation/reimplantation. After mobilization of the anomalous coronary artery, a transection with an aortic button and reimplantation in the “correct” sinus of Valsalva using an aortic punch is performed. **C**, Coronary ostioplasty. After transection of the aortic wall, an incision from the cut edge of the aorta is made into the ostium of the anomalous coronary artery and further extended into the artery itself. Then, a patch is sutured into this incision, resulting in the creation of a neo-ostium as well as an enlarged proximal segment. **D**, Pulmonary artery translocation. The main pulmonary artery is divided at its bifurcation and moved to the left, while a patch suture enlarges the pulmonary artery confluence (lateral approach). Alternatively, pulmonary artery translocation can be performed by moving the pulmonary arteries anterior to the aorta (anterior approach also called modified LeCompte maneuver). Panel (**A**) is adapted from Borns et al. *Front Cardiovasc Med*. 2021 Jan 21;7:591326. All images are drawn by Professor Alexander Kadner. LCA indicates left coronary artery; and LPA, left pulmonary artery.

a new and wider coronary ostium in the appropriate sinus and additional enlarging of the proximal vessel course, coronary angioplasty directly addresses all anatomic high-risk features.^{96,98} However, similar to coronary translocation, coronary ostioplasty is a technically challenging procedure, where a high expertise is required, and long-term follow-up data on the application of a patch in the coronary circulation are missing. Concerns about thrombus formation in addition to aneurysmal alterations of the patch have been rarely reported.^{96,99}

Coronary Artery Bypass Graft Surgery

Standard coronary artery bypass grafting (CABG) is a well-established surgical procedure for treatment of CAD and is preferred in certain circumstances of patients with ACAOS. Compared with unroofing or coronary translocation/ostoplasty, no manipulations at the aorta or near the aortic valve are needed in

CABG, thus reducing procedural risks.⁶⁴ Although from the pathophysiologic point of view CABG addresses all anatomic high-risk features, as it directly eliminates the anomalous segment, several important limitations have to be considered to this approach. First and most important, there is an increased risk of coronary bypass failure based on the competitive flow through the native anomalous segment.^{64,76,100–103} In fact, a high graft failure rate has been described in the literature,^{103–107} and therefore proximal ligation of the anomalous coronary artery has been described as a crucial step for CABG patency.^{64,76,85,105,108} An important drawback of this procedure is the complete dependence of the anomalous supplied myocardium on a graft and anastomosis with uncertain durability and, especially important in young patients, uncertain growth potential.^{64,103} Hence, several studies propose that CABG should be limited to only those patients with concomitant, significant CAD within the anomalous vessel.^{85,104,108}

Pulmonary Artery Translocation

The pulmonary artery translocation approach is characterized by dividing the main pulmonary artery at its bifurcation and shifting leftward, while a patch suture enlarges the pulmonary artery confluence (Figure 3D). Alternatively, pulmonary artery translocation can be performed by moving the pulmonary arteries anterior to the aorta (modified LeCompte maneuver).^{58,109–111} Both procedures result in the creation of additional space between the great arteries,¹¹² addressing the historically believed compression of the anomalous segment between the great arteries. However, this mechanism is unlikely considering the pressure condition in the respective circulatory systems. Further, pulmonary artery translocation does not address any of the other anatomic high-risk features. Indeed, most of the reported (successful) applications of this technique were in combination with unroofing or in patients with the interarterial course as the only risk factor (ie, with unclear hemodynamic significance of the ACAOS).¹¹¹ Hence, from the pathophysiologic point of view, there is no indication for this procedure in patients with ACAOS.

Percutaneous Coronary Intervention

There is limited evidence for the use of percutaneous coronary intervention (PCI) in the setting of ACAOS.^{37,43,113–118} In most case reports, PCI targets atherosclerotic lesions distal to the anomalous segment, and thus it does not represent a corrective treatment of ACAOS itself.^{50,119,120} There is 1 clinical trial describing PCI in 42 middle-aged and older patients with R-ACAOS, where stenting was conducted under intravascular ultrasound guidance.³⁷ The authors aimed at covering the entire intramural segment with a single stent matched with the distal reference diameter. They successfully increased the cross-sectional area of the intramural segment from 4.8 mm² to 10.8 mm² (mean distal reference cross-sectional area=12.4 mm²) when applying this approach. Further, lateral compression as well as phasic pulsatility were eliminated after stent deployment.³⁷ PCI address mainly the slitlike ostium, the proximal narrowing, and the lateral compression of the intramural segment, while the acute take-off angle is not touched (Figure 4). Of note, there is no evidence of the behavior of a stent exposed to prolonged and repeated external dynamic compression in such circumstances, and more importantly, there is currently no indication for this procedure in a pediatric and young patient population considering the coronary growth and unknown long-term results. However, whether this approach might be an alternative in patients less suitable for surgery is unclear, as long-term outcome after stent implantation in the intramural segment remains unclear. In fact, 40% (4/10) of the patients who

underwent clinically indicated follow-up coronary angiography demonstrated relevant restenosis requiring revascularization in the above-mentioned study.³⁷ Therefore, PCI is currently rather an ultimate option in nonsurgical candidates until more evidence is available from future trials on the long-term patency of PCI in ACAOS. However, it is plausible that with this growing evidence, PCI will become a valuable therapeutic option for the treatment of ACAOS, especially in older patients.

Conservative Management

Based on the pathophysiology with exercise-dependent aggravation of the flow restriction (ie, the dynamic component), a conservative management with sports restriction and medical therapy (ie, beta-blocker^{121,122}) is possible but should not be promoted as the first-line therapy. In fact, most institutions recommend these measures only for bridging patients until the surgical intervention is performed or in cases in which affected patients declined an operation or an operation is not feasible.^{53,57,61,92,121} Especially for young patients, long-term exercise restriction or beta-blocker therapy can represent a radical limitation with subsequent negative emotional and health aspects.^{9,53,66,123,124} Hence, conservative management is not an option for athletes or young, active individuals. Accurate diagnostic assessment is crucial, as patients with variants and absence of hemodynamic relevance should not be limited in their sports behavior.²² Finally, reports of sudden cardiac arrest have been reported even after surgical therapy of the anomaly.^{60,72} As a reason for this, an incomplete revascularization⁵³ or a possible underlying arrhythmogenic substrate in ACAOS with previous myocardial damage have to be considered. Therefore, the addition of antiarrhythmic medication (eg, beta-blocker) might be considered in such circumstances.

PROPOSED THERAPEUTIC MANAGEMENT ALGORITHM

Based on the pathophysiology of ACAOS, we propose the following therapeutic management algorithm aiming at correcting the different anatomic high-risk features and restoring hemodynamic physiology (Figure 5). The certitude whether ACAOS with anatomic high-risk features (ie, including 1 or multiple features: interarterial course, intramural course, acute take-off angle, slitlike ostium, proximal narrowing, proximal elliptical vessel shape) is a coincidental or a hemodynamically relevant finding is the first and most prominent step in the decision making toward the appropriate therapeutic management. ACAOS-related myocardial ischemia by FFR ≤ 0.80 or minimal lumen area reduction of $>50\%$ in IVUS using a dobutamine/volume challenge or presence of ischemia

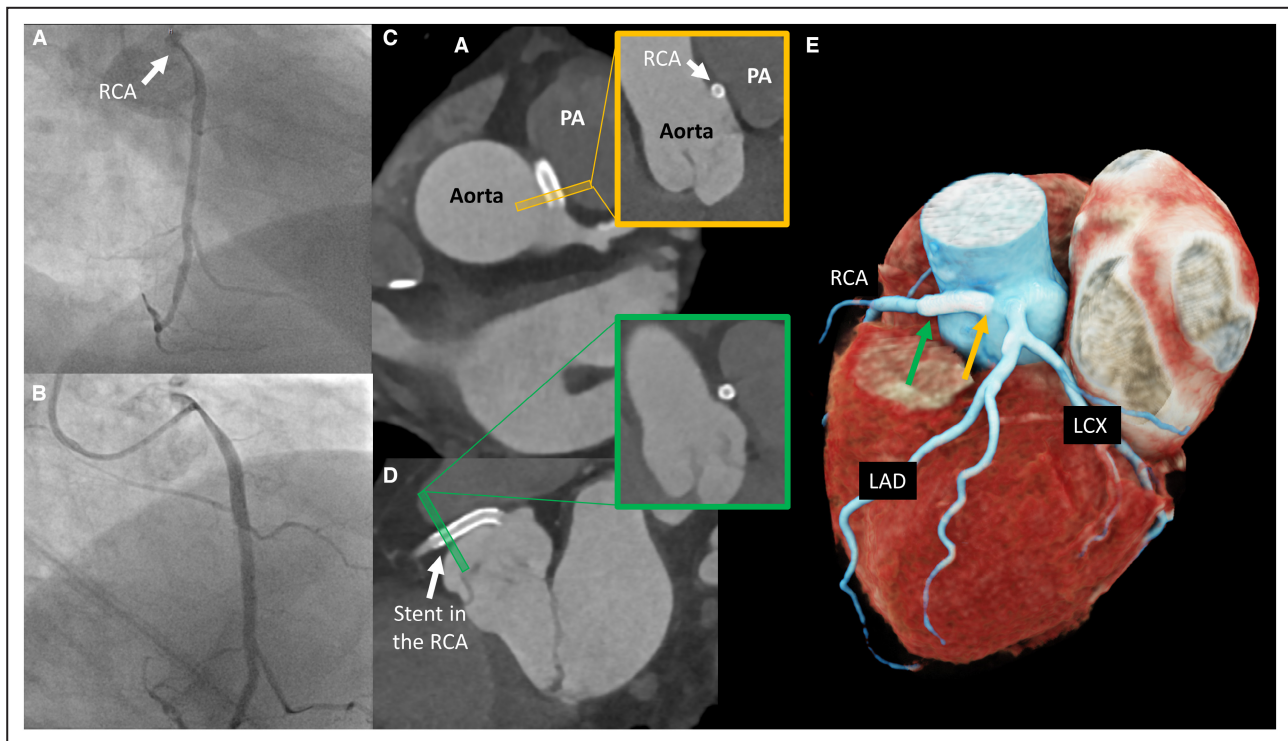


Figure 4. Illustration of a percutaneous coronary intervention in a right anomalous coronary artery originating from the opposite sinus of Valsalva. (A and B).

Invasive coronary angiography illustrating the proximal narrowing within the intramural course from two projections (A, right anterior oblique 40°, caudal 8°; and B, right anterior oblique 46°, cranial 4°). C and D, Postinterventional CCTA illustrating the correct placement of the 2 stents within the intramural course. C, ostial cross-section, D, distal cross-section. E, 3-dimensional reconstruction from the postinterventional CCTA-images. CCTA indicates coronary computed tomography angiography; LAD, left anterior descending (coronary artery); LCX, left circumflex (coronary artery); PA, pulmonary artery; and RCA, right coronary artery.

in noninvasive imaging is an indication for correction of the anomalous vessel.^{30,49} If the patient is asymptomatic and does not show any ACAOS-related ischemia, no further actions are advised. However, in symptomatic patients with nonhemodynamically relevant ACAOS, other underlying causes of the symptoms (eg, nonanomalous CAD) should be investigated before a case-by-case decision is made toward ACAOS correction or not. In all cases with hemodynamically relevant ACAOS, the subsequent step involves the assessment of presence or absence of concomitant CAD. If needed and in unclear cases, fused/hybrid cardiac imaging can help in the distinction of anomalous versus nonanomalous vessel-related ischemia.^{30,49} In addition, sports restrictions (particularly competitive sports) are recommended during this diagnostic and therapeutic process. Based on the information from noninvasive and invasive imaging on the presence and extent of anatomic high-risk features,²² the optimal surgical therapy is selected.^{8,22,125}

Presence of an Intramural Course

In the situation of a long intramural course from the wrong sinus up to the appropriate sinus of Valsalva, above the commissure, unroofing is the recommended

approach. In cases with a short intramural course limited within the wrong sinus of Valsalva, or in cases with a long intramural course but a course below the commissure, the formation of a neo-ostium or a coronary translocation would be an alternative strategy to unroofing. Of note, decision for creation of a neo-ostium or coronary translocation depends on the attainable angle of the neo-take-off. Further, in situations in which relevant proximal narrowing exceeds the intramural course, an additional patch angioplasty should be considered.

Absence of an Intramural Course

Absence of an intramural course requires alternative treatment strategies, as the surgical technique with the best level of evidence, that is, coronary unroofing, is not applicable. In the combination of the absence of the intramural course and absence of a slitlike ostium and proximal narrowing, coronary translocation and considering additional patch angioplasty of the anomalous coronary artery is the recommended surgical procedure. In the situation of the presence of a slitlike ostium or proximal narrowing (ie, both features representing a fixed component and thus causing flow

restrictions similar to a fixed stenosis known from atherosclerotic lesions), coronary translocation with or without patch ostioplasty should be the best choice for children and adolescents, while CABG should be considered in older patients, as competitive flow will not limit graft patency. Alternatively, in the situation of a proximal narrowing as the only culprit feature, PCI may be considered in the older population with high operative risk as a valuable ultima ratio alternative.

demonstrated hemodynamic relevance of the ectopic course, CABG is the recommended therapy of choice as the risk of graft failure attributable to low competing flow through the native vessel vanishes. In the case of CAD in nonanomalous coronary arteries, CAD should be addressed as recommended by the guidelines on myocardial revascularization^{1,126,127} (CABG or PCI), whereas ACAOS should be treated according to anatomic features.

Presence of Concomitant CAD

With increasing age, concomitant CAD gains importance and impacts on the therapeutic decision.⁴⁹ In such situations, fused/hybrid cardiac imaging helps to differentiate between CAD-related from ACAOS-related perfusion deficits.^{30,49} In cases of atherosclerotic lesions within the anomalous vessels and a

Eligibility for Sports

Based on the evidence from autopsy studies, where ACAOS is one of the leading causes of sports-related SCD, strenuous exercise should be avoided in suspected cases of hemodynamically relevant ACAOS until completion of a workup.^{18,21} However, considering the required supramaximal testing to demonstrated

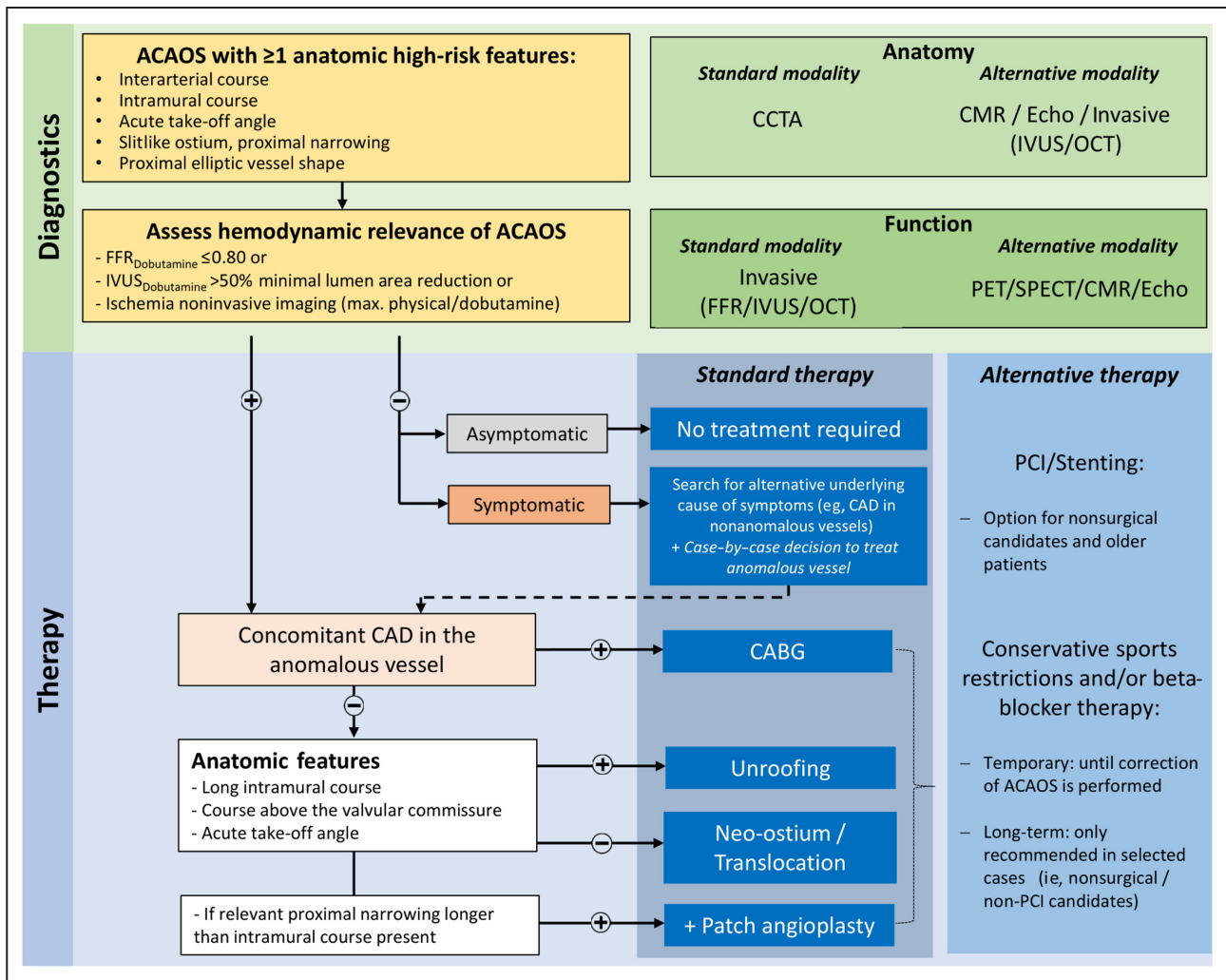


Figure 5. Flow chart of the therapeutic management in patients with an anomalous coronary artery and confirmed myocardial ischemia related to ACAOS.

ACAOS indicates anomalous coronary artery originating from the opposite sinus of Valsalva; CAD, coronary artery disease; CABG, coronary artery bypass grafting; CCTA, coronary computed tomography angiography; CMR, cardiovascular magnetic resonance imaging; FFR, fractional flow reserve; IVUS, intravascular ultrasound; OCT, optical coherence tomography; PCI, percutaneous coronary intervention; PET, positron emission tomography; and SPECT, single-photon emission computed tomography.

Downloaded from http://ahajournals.org by on October 14, 2022

hemodynamic relevance,^{22,73} low-intensity sports (eg, golf, yoga) are allowed in all cases if asymptomatic.^{18,21} After surgical correction and exclusion of proarrhythmic substrates, resumption of competitive sports is safe after an appropriate recovery period (eg, 3 months^{18,21}).

GAPS OF KNOWLEDGE

As most of the evidence of therapeutic management in ACAOS is based on small studies/registries, case series, or case reports, the following gaps of knowledge and future research questions aiming at improving evidence-based treatment of ACAOS are highlighted below. Ongoing large single-center and multicenter registries, currently actively recruiting patients, will ideally provide clarifying data for the improvement of the decision making in this clinical setting.^{128,129}

1. In which situations is a surgical intervention required in patients with ACAOS, and what are the most important clinical and imaging findings for the indication of a surgical correction?
2. What is the long-term outcome of the different surgical approaches? Does the anatomic correction versus conservative treatment result only in symptom relief, or can cardiac death be improved as well?
3. What is the optimal method to assess and evaluate the anatomic high-risk features? A universal definition including standardized assessments and thresholds is required.
4. Which patients may be candidates for conservative medical treatment?
5. In which patients does PCI represent a possible minimally invasive treatment option?
6. Should patients with myocardial damage attributable to ACAOS (ie, scarring as an underlying possible arrhythmogenic substrate) be treated surgically and with antiarrhythmic drugs or even with an implantable cardioverter defibrillator?
7. How should patients with surgically corrected ACAOS be followed up?
8. How should we manage asymptomatic patients with hemodynamically relevant ACAOS, and how should we treat symptomatic patients with no hemodynamically relevant ACAOS?
9. Is the application of the adopted FFR threshold of 0.80 as a decision-making tool in ACAOS associated with an improved outcome, as previously demonstrated in the CAD population? What is an optimal cutoff of ischemia burden in nonischemic testing to decide toward ACAOS correction?
10. Coronary dominance determines the location and amount of myocardium perfused by the

right or left coronary artery (right or left dominance). The correlation between ACAOS, coronary dominance, and ischemic presentation is still unknown. Further studies are needed to evaluate this potential additional risk factor.

11. What is the best method to assess the success of surgical correction intraoperatively?

CONCLUSIONS

Thorough anatomic and hemodynamic assessment of patients with ACAOS is needed to guide optimal therapeutic management. Because of the heterogeneous presentation of ACAOS, usually an interdisciplinary case-by-case decision is made on the basis of multimodality imaging to tailor the optimal therapeutic management. In patients with ACAOS and a long intramural anomalous vessel course and proven hemodynamic relevance, surgical unroofing is the recommended approach. On the contrary, in cases with ischemia and short or absence of the intramural course, coronary translocation or ostioplasty represent the optimal surgical methods. In patients with concomitant CAD within the anomalous vessel, CABG or PCI may be considered as a therapeutic option. Of note, evidence on the therapeutic management in general is limited, and major efforts have to be made to collect data from multinational ACAOS registries with accurate pre- and postoperative diagnostics to increase evidence-based decision making in this clinical setting.

ARTICLE INFORMATION

Affiliations

Department of Cardiology, Inselspital, Bern University Hospital, University of Bern, Bern, Switzerland (M.R.B., L.R., A.A., S.W., C.G.); Centre for Congenital Heart Disease, Department of Cardiovascular Surgery, Inselspital, Bern, Switzerland (A.K., M.S.); and Section of Pediatric and Congenital Cardiac Surgery, Department of Cardio-Thoracic and Vascular Sciences, and Public Health, University of Padova, Medical School, Padova, Italy (M.A.P.).

Sources of Funding

This work was supported by the Swiss National Science Foundation Grant Number 200871, NARCO (Noninvasive Anatomical Assessment for Ruling Out Hemodynamically Relevant Coronary Artery anomalies - A Comparison of Coronary CT to Invasive Coronary Angiography) to Dr Gräni.

Disclosures

Dr Räber received research grants to the institution by Abbott Vascular, Biotronik, Boston Scientific, Medis, Sanofi, and Regeneron; and consultation/speaker fees by Abbott Vascular, Amgen, AstraZeneca, Canon, Occlutech, and Vifor. Dr Windecker reports research and educational grants to the institution from Abbott, Amgen, BMS, Bayer, Boston Scientific, Biotronik, Cardinal Health, CardioValve, CSL Behring, Daiichi Sankyo, Edwards Lifesciences, Johnson & Johnson, Medtronic, Querbet, Polares, Sanofi, Terumo, and Sinomed. Dr Windecker serves as an unpaid member of the steering/executive group of trials funded by Abbott, Abiomed, Amgen, BMS, Boston Scientific, Biotronik, Cardiovalve, Edwards Lifesciences, MedAlliance, Medtronic, Polares, Sinomed, V-Wave, and Xeltis, but has not received personal payments by any pharmaceutical company or device manufacturer. He is also member of the steering/executive committee group of several investigated-initiated trials that receive funding by industry

without impact on his personal remuneration. Dr Gräni reports research grant from the Swiss National Science Foundation and InnoSuisse. The remaining authors have no disclosures to report.

ENDNOTE

† References 11,28,45,51,53,54,58–60,62,63,65,67,77–89.

REFERENCES

- Knuuti J, Wijns W, Saraste A, Capodanno D, Barbato E, Funck-Brentano C, Prescott E, Storey RF, Deaton C, Cuisset T, et al. 2019 ESC guidelines for the diagnosis and management of chronic coronary syndromes: the task force for the diagnosis and management of chronic coronary syndromes of the European Society of Cardiology (ESC). *Eur Heart J*. 2019;41:407–477. doi: 10.1093/eurheartj/ehz425
- Angelini P, Vidovich MI, Lawless CE, Elyada MA, Lopez JA, Wolf D, Willerson JT. Preventing sudden cardiac death in athletes: in search of evidence-based, cost-effective screening. *Tex Heart Inst J*. 2013;40:148–155.
- Grani C, Benz DC, Schmied C, Vontobel J, Possner M, Clerc OF, Mikulicic F, Stehli J, Fuchs TA, Pazhenkottil AP, et al. Prevalence and characteristics of coronary artery anomalies detected by coronary computed tomography angiography in 5634 consecutive patients in a single centre in Switzerland. *Swiss Med Wkly*. 2016;146:w14294
- Angelini P, Uribe C. Critical update and discussion of the prevalence, nature, mechanisms of action, and treatment options in potentially serious coronary anomalies. *Trends Cardiovasc Med*. 2022;26. [epub ahead of print]
- Angelini P. Coronary artery anomalies: an entity in search of an identity. *Circulation*. 2007;115:1296–1305. doi: 10.1161/CIRCULATIONAHA.106.618082
- Basso C, Maron BJ, Corrado D, Thiene G. Clinical profile of congenital coronary artery anomalies with origin from the wrong aortic sinus leading to sudden death in young competitive athletes. *J Am Coll Cardiol*. 2000;35:1493–1501. doi: 10.1016/S0735-1097(00)00566-0
- Eckart RE, Scoville SL, Campbell CL, Shry EA, Stajduhar KC, Potter RN, Pearse LA, Virmani R. Sudden death in young adults: a 25-year review of autopsies in military recruits. *Ann Intern Med*. 2004;141:829–834. doi: 10.7326/0003-4819-141-11-200412070-00005
- Lim JC, Beale A, Ramcharitar S. Anomalous origination of a coronary artery from the opposite sinus. *Nat Rev Cardiol*. 2011;8:706–719. doi: 10.1038/nrcardio.2011.147
- Mirchandani S, Phoon CK. Management of anomalous coronary arteries from the contralateral sinus. *Int J Cardiol*. 2005;102:383–389. doi: 10.1016/j.ijcard.2004.10.010
- Gentile F, Castiglione V, De Caterina R. Coronary artery anomalies. *Circulation*. 2021;144:983–996. doi: 10.1161/CIRCULATIONAHA.121.055347
- Brothers JA, Frommelt MA, Jaquiss RDB, Myerburg RJ, Fraser CD Jr, Tweddell JS. Expert consensus guidelines: anomalous aortic origin of a coronary artery. *J Thorac Cardiovasc Surg*. 2017;153:1440–1457. doi: 10.1016/j.jtcvs.2016.06.066
- Maron BJ, Doerer JJ, Haas TS, Tierney DM, Mueller FO. Sudden deaths in young competitive athletes: analysis of 1866 deaths in the United States, 1980–2006. *Circulation*. 2009;119:1085–1092. doi: 10.1161/CIRCULATIONAHA.108.804617
- Grani C, Benz DC, Steffen DA, Clerc OF, Schmied C, Possner M, Vontobel J, Mikulicic F, Gebhard C, Pazhenkottil AP, et al. Outcome in middle-aged individuals with anomalous origin of the coronary artery from the opposite sinus: a matched cohort study. *Eur Heart J*. 2017;38:2009–2016. doi: 10.1093/eurheartj/ehx046
- Cheezum MK, Liberthson RR, Shah NR, Villines TC, O'Gara PT, Landzberg MJ, Blankstein R. Anomalous aortic origin of a coronary artery from the inappropriate sinus of Valsalva. *J Am Coll Cardiol*. 2017;69:1592–1608. doi: 10.1016/j.jacc.2017.01.031
- Grani C, Buechel RR, Kaufmann PA, Kwong RY. Multimodality imaging in individuals with anomalous coronary arteries. *J Am Coll Cardiol Img*. 2017;10:471–481. doi: 10.1016/j.jcmg.2017.02.004
- Grani C, Kaufmann PA, Windecker S, Buechel RR. Diagnosis and management of anomalous coronary arteries with a malignant course. *Interv Cardiol (London, England)*. 2019;14:83–88. doi: 10.15420/icr.2019.1.1
- Warnes CA, Williams RG, Bashore TM, Child JS, Connolly HM, Dearani JA, Nido P, Fasules JW, Graham TP, Hijazi ZM, et al. ACC/AHA 2008 Guidelines for the management of adults with congenital heart disease. *Circulation*. 2008;118:e714–e833.
- Van Hare GF, Ackerman MJ, J-aK E, Kovacs RJ, Myerburg RJ, Shafer KM, Warnes CA, Washington RL. Eligibility and disqualification recommendations for competitive athletes with cardiovascular abnormalities: task force 4: congenital heart disease: a scientific statement from the American Heart Association and American College of Cardiology. *Circulation*. 2015;132:e281–e291. doi: 10.1161/CIR.0000000000000240
- Stout KK, Daniels CJ, Aboulhosn JA, Bozkurt B, Broberg CS, Colman JM, Crumb SR, Dearani JA, Fuller S, Gurvitz M, et al. 2018 AHA/ACC guideline for the management of adults with congenital heart disease: executive summary: a report of the American College of Cardiology/American Heart Association task force on clinical practice guidelines. *Circulation*. 2019;139:e637–e697. doi: 10.1161/CIR.0000000000000602
- Baumgartner H, De Backer J, Babu-Narayan SV, Budts W, Chessa M, Diller G-P, Lung B, Kluin J, Lang IM, Meijboom F, et al. ESC guidelines for the management of adult congenital heart disease: the task force for the management of adult congenital heart disease of the European Society of Cardiology (ESC). *Eur Heart J*. 2020;2021(42):563–645. doi: 10.1093/eurheartj/ehaa554
- Pelliccia A, Sharma S, Gati S, Bäck M, Börjesson M, Caselli S, Collet JP, Corrado D, Drezner JA, Halle M, et al. ESC guidelines on sports cardiology and exercise in patients with cardiovascular disease. *Eur Heart J*. 2020;202(42):17–96.
- Bigler MR, Ashraf A, Seiler C, Praz F, Ueki Y, Windecker S, Kadner A, Råber L, Gräni C. Hemodynamic relevance of anomalous coronary arteries originating from the opposite sinus of Valsalva-in search of the evidence. *Front Cardiovasc Med*. 2021;7:591326. doi: 10.3389/fcvm.2020.591326
- Angelini P, Uribe C. Anatomic spectrum of left coronary artery anomalies and associated mechanisms of coronary insufficiency. *Catheter Cardiovasc Interv*. 2018;92:313–321. doi: 10.1002/ccd.27656
- Angelini P, Velasco JA, Ott D, Khoshnevis GR. Anomalous coronary artery arising from the opposite sinus: descriptive features and pathophysiological mechanisms, as documented by intravascular ultrasonography. *J Invasive Cardiol*. 2003;15:507–514.
- Jegatheeswaran A, Devlin PJ, McCrindle BW, Williams WG, Jacobs ML, Blackstone EH, DeCampi WM, Caldaroni CA, Gaynor JW, Kirklint JK, et al. Features associated with myocardial ischemia in anomalous aortic origin of a coronary artery: a Congenital Heart Surgeons' Society study. *J Thorac Cardiovasc Surg*. 2019;158:822–834.e3. doi: 10.1016/j.jtcvs.2019.02.122
- Brothers JA, Whitehead KK, Keller MS, Fogel MA, Paridon SM, Weinberg PM, Harris MA. Cardiac MRI and CT: differentiation of normal ostium and intraseptal course from slitlike ostium and interarterial course in anomalous left coronary artery in children. *AJR Am J Roentgenol*. 2015;204:W104–W109. doi: 10.2214/AJR.14.12953
- Angelini P. Coronary artery anomalies—current clinical issues: definitions, classification, incidence, clinical relevance, and treatment guidelines. *Tex Heart Inst J*. 2002;29:271–278.
- Davies JE, Burkhart HM, Dearani JA, Suri RM, Phillips SD, Warnes CA, Sundt TM III, Schaff HV. Surgical management of anomalous aortic origin of a coronary artery. *Ann Thorac Surg*. 2009;88:844–847; discussion 847–8.
- Davis JA, Cecchin F, Jones TK, Portman MA. Major coronary artery anomalies in a pediatric population: incidence and clinical importance. *J Am Coll Cardiol*. 2001;37:593–597. doi: 10.1016/S0735-1097(00)01136-0
- Gräni C, Benz DC, Schmied C, Vontobel J, Mikulicic F, Possner M, Clerc OF, Stehli J, Fuchs TA, Pazhenkottil AP, et al. Hybrid CCTA/SPECT myocardial perfusion imaging findings in patients with anomalous origin of coronary arteries from the opposite sinus and suspected concomitant coronary artery disease. *J Nucl Cardiol*. 2017;24:226–234. doi: 10.1007/s12350-015-0342-x
- Ripley DP, Saha A, Teis A, Uddin A, Bijsterveld P, Kidambi A, McDiarmid AK, Sivananthan M, Plein S, Pennell DJ, et al. The distribution and prognosis of anomalous coronary arteries identified by cardiovascular magnetic resonance: 15 year experience from two tertiary centres. *J Cardiovasc Magn Reson*. 2014;16:34. doi: 10.1186/1532-429X-16-34
- Cheezum MK, Ghoshhajra B, Bittencourt MS, Hulten EA, Bhatt A, Mousavi N, Shah NR, Valente AM, Rybicki FJ, Steigner M, et al.

- Anomalous origin of the coronary artery arising from the opposite sinus: prevalence and outcomes in patients undergoing coronary CTA. *Eur Heart J Cardiovasc Imaging*. 2017;18:224–235. doi: 10.1093/ehjci/jev323
33. Taylor AJ, Rogan KM, Virmani R. Sudden cardiac death associated with isolated congenital coronary artery anomalies. *J Am Coll Cardiol*. 1992;20:640–647. doi: 10.1016/0735-1097(92)90019-J
 34. Cheitlin MD, De Castro CM, McAllister HA. Sudden death as a complication of anomalous left coronary origin from the anterior sinus of Valsalva, A not-so-minor congenital anomaly. *Circulation*. 1974;50:780–787. doi: 10.1161/01.CIR.50.4.780
 35. Taylor AJ, Byers JP, Cheitlin MD, Virmani R. Anomalous right or left coronary artery from the contralateral coronary sinus: "high-risk" abnormalities in the initial coronary artery course and heterogeneous clinical outcomes. *Am Heart J*. 1997;133:428–435. doi: 10.1016/S0002-8703(97)70184-4
 36. Diao KY, Zhao Q, Gao Y, Shi K, Ma M, Xu HY, Guo YK, Yang ZG. Prognostic value of dual-source computed tomography (DSCT) angiography characteristics in anomalous coronary artery from the opposite sinus (ACAOs) patients: a large-scale retrospective study. *BMC Cardiovasc Disord*. 2020;20:25. doi: 10.1186/s12872-019-01285-3
 37. Angelini P, Uribe C, Monge J, Tobis JM, Elayda MA, Willerson JT. Origin of the right coronary artery from the opposite sinus of Valsalva in adults: characterization by intravascular ultrasonography at baseline and after stent angioplasty. *Catheter Cardiovasc Interv*. 2015;86:199–208. doi: 10.1002/ccd.26069
 38. Tonino PA, De Bruyne B, Pijls NH, Siebert U, Ikeno F, van't Veer M, Klauss V, Manoharan G, Engstrom T, Oldroyd KG, et al. Fractional flow reserve versus angiography for guiding percutaneous coronary intervention. *N Engl J Med*. 2009;360:213–224. doi: 10.1056/NEJMoa0807611
 39. Angelini P, Flamm SD. Newer concepts for imaging anomalous aortic origin of the coronary arteries in adults. *Catheter Cardiovasc Interv*. 2007;69:942–954. doi: 10.1002/ccd.21140
 40. Angelini P, Uribe C. Symptomatic right coronary anomaly with dynamic systolic intramural obliteration and isolated right ventricular ischemia. *Catheter Cardiovasc Interv*. 2019;93:445–447. doi: 10.1002/ccd.28028
 41. Lee SE, Yu CW, Park K, Park KW, Suh JW, Cho YS, Youn TJ, Chae IH, Choi DJ, Jang HJ, et al. Physiological and clinical relevance of anomalous right coronary artery originating from left sinus of Valsalva in adults. *Heart*. 2016;102:114–119. doi: 10.1136/heartjnl-2015-308488
 42. Boler AN, Hilliard AA, Gordon BM. Functional assessment of anomalous right coronary artery using fractional flow reserve: an innovative modality to guide patient management. *Catheter Cardiovasc Interv*. 2017;89:316–320. doi: 10.1002/ccd.26660
 43. Tsujita K, Maehara A, Mintz GS, Franklin-Bond T, Mehran R, Stone GW, Leon MB, Moses JW. In vivo intravascular ultrasonic assessment of anomalous right coronary artery arising from left coronary sinus. *Am J Cardiol*. 2009;103:747–751. doi: 10.1016/j.amjcard.2008.11.016
 44. de Oliveira DM, Gomes V, Caramori P. Intravascular ultrasound and pharmacological stress test to evaluate the anomalous origin of the right coronary artery. *J Invasive Cardiol*. 2012;24:E131–E134.
 45. Kaushal S, Backer CL, Popescu AR, Walker BL, Russell HM, Koenig PR, Rigsby CK, Mavroudis C. Intramural coronary length correlates with symptoms in patients with anomalous aortic origin of the coronary artery. *Ann Thorac Surg*. 2011;92:986–991; discussion 991–2.
 46. Frommelt PC, Sheridan DC, Berger S, Frommelt MA, Tweddell JS. Ten-year experience with surgical unroofing of anomalous aortic origin of a coronary artery from the opposite sinus with an interarterial course. *J Thorac Cardiovasc Surg*. 2011;142:1046–1051. doi: 10.1016/j.jtcvs.2011.02.004
 47. Harris MA, Whitehead KK, Shin DC, Keller MS, Weinberg PM, Fogel MA. Identifying abnormal ostial morphology in anomalous aortic origin of a coronary artery. *Ann Thorac Surg*. 2015;100:174–179. doi: 10.1016/j.athoracsur.2015.02.031
 48. Cheitlin MD, MacGregor J. Congenital anomalies of coronary arteries: role in the pathogenesis of sudden cardiac death. *Herz*. 2009;34:268–279. doi: 10.1007/s00059-009-3239-0
 49. Grani C, Benz DC, Possner M, Clerc OF, Mikulicic F, Vontobel J, Stehli J, Fuchs TA, Pazhenkottil AP, Gaemperli O, et al. Fused cardiac hybrid imaging with coronary computed tomography angiography and positron emission tomography in patients with complex coronary artery anomalies. *Congenit Heart Dis*. 2017;12:49–57. doi: 10.1111/chd.12402
 50. Bigler MR, Huber AT, Råber L, Grani C. A case report of a symptomatic right anomalous coronary artery with concomitant atherosclerotic disease: the benefit of a sequential comprehensive non-invasive and invasive diagnostic approach. *Eur Heart J Case Rep* 2021;5:ytab081. doi: 10.1093/ehjcr/ytab081.
 51. Mostefa Kara M, Fournier E, Cohen S, Hascoet S, Van Aerschot I, Roussin R, El Zoghbi J, Belli E. Anomalous aortic origin of coronary arteries: is the unroofing procedure always appropriate? *Eur J Cardiothorac Surg*. 2021;59:705–710. doi: 10.1093/ejcts/ezaa379
 52. Jegatheeswaran A, Devlin PJ, Williams WG, Brothers JA, Jacobs ML, DeCampi WM, Fleishman CE, Kirklín JK, Mertens L, Mery CM, et al. Outcomes after anomalous aortic origin of a coronary artery repair: a congenital heart surgeons' society study. *J Thorac Cardiovasc Surg*. 2020;160:757–771.e5. doi: 10.1016/j.jtcvs.2020.01.114
 53. Mery CM, De León LE, Molossi S, Sexson-Tejtel SK, Agrawal H, Krishnamurthy R, Masand P, Qureshi AM, McKenzie ED, Fraser CD Jr. Outcomes of surgical intervention for anomalous aortic origin of a coronary artery: a large contemporary prospective cohort study. *J Thorac Cardiovasc Surg*. 2018;155:305–319.e4. doi: 10.1016/j.jtcvs.2017.08.116
 54. Padalino MA, Franchetti N, Hazekamp M, Sojak V, Carrel T, Frigiola A, Lo Rito M, Horer J, Roussin R, Cleuziou J, et al. Surgery for anomalous aortic origin of coronary arteries: a multicentre study from the European Congenital Heart Surgeons Association¹. *Eur J Cardiothorac Surg*. 2019;56:696–703. doi: 10.1093/ejcts/ezz080
 55. Fabozzo A, DiOrto M, Newburger JW, Powell AJ, Liu H, Fynn-Thompson F, Sanders SP, Pigula FA, Del Nido PJ, Nathan M. Anomalous aortic origin of coronary arteries: a single-center experience. *Semin Thorac Cardiovasc Surg*. 2016;28:791–800. doi: 10.1053/j.semtcvs.2016.08.012
 56. Poynter JA, Bondarenko I, Austin EH, DeCampi WM, Jacobs JP, Ziemer G, Kirshbom PM, Tchervenkov CI, Karamlou T, Blackstone EH, et al. Repair of anomalous aortic origin of a coronary artery in 113 patients: a Congenital Heart Surgeons' Society report. *World J Pediatr Congenit Heart Surg*. 2014;5:507–514. doi: 10.1177/2150135114540182
 57. Courand P-Y, Bozio A, Ninet J, Boussel L, Bakloul M, Galoin-Bertail C, Metton O, Mitchell J, de Montclos TP, Walton C, et al. Diagnosis and treatment of anomalous aortic origin of coronary artery: a twenty-year retrospective study of experience and decision-making in children and young adults. *Int J Cardiol*. 2021;337:54–61. doi: 10.1016/j.ijcard.2021.04.066
 58. Mainwaring RD, Reddy VM, Reinhartz O, Petrossian E, Punn R, Hanley FL. Surgical repair of anomalous aortic origin of a coronary artery. *Eur J Cardiothorac Surg*. 2014;46:20–26. doi: 10.1093/ejcts/ezt614
 59. Sharma V, Burkhart HM, Dearani JA, Suri RM, Daly RC, Park SJ, Horner JM, Phillips SD, Schaff HV. Surgical unroofing of anomalous aortic origin of a coronary artery: a single-center experience. *Ann Thorac Surg*. 2014;98:941–945. doi: 10.1016/j.athoracsur.2014.04.114
 60. Sachdeva S, Frommelt MA, Mitchell ME, Tweddell JS, Frommelt PC. Surgical unroofing of intramural anomalous aortic origin of a coronary artery in pediatric patients: single-center perspective. *J Thorac Cardiovasc Surg*. 2018;155:1760–1768. doi: 10.1016/j.jtcvs.2017.11.003
 61. Kaku B, Shimizu M, Yoshio H, Ino H, Mizuno S, Kanaya H, Ishise S, Mabuchi H. Clinical features of prognosis of Japanese patients with anomalous origin of the coronary artery. *Jpn Circ J*. 1996;60:731–741. doi: 10.1253/jcj.60.731
 62. Feins EN, DeFaria Yeh D, Bhatt AB, Stefanescu A, Youniss MA, Ghoshhajra BB, Inglessis-Azuaje I, Liberthson RR and MacGillivray TE. Anomalous aortic origin of a coronary artery: surgical repair with anatomic- and function-based follow-up. *Ann Thorac Surg*. 2016;101:169–175; discussion 175–6.
 63. Mumtaz MA, Lorber RE, Arruda J, Pettersson GB and Mavroudis C. Surgery for anomalous aortic origin of the coronary artery. *Ann Thorac Surg*. 2011;91:811–814; discussion 814–5.
 64. Ibraheem WI, Abass OA, Toema AM, Yehia AM. Coronary artery bypass grafting experience in the setting of an anomalous origin of the right coronary artery from the left sinus of Valsalva: midterm results. *J Card Surg*. 2019;34:1162–1171. doi: 10.1111/jocs.14234
 65. Borns J, Grani C, Kadner A, Gloeckler M, Pfammatter JP. Symptomatic coronary anomalies and ischemia in teenagers - rare but real. *Front Cardiovasc Med*. 2020;7:559794. doi: 10.3389/fcvm.2020.559794.
 66. Mery CM, Lopez KN, Molossi S, Sexson-Tejtel SK, Krishnamurthy R, McKenzie ED, Fraser CD Jr, Cantor SB. Decision analysis to define the optimal management of athletes with anomalous aortic origin of a coronary artery. *J Thorac Cardiovasc Surg*. 2016;152:1366–1375.e7. doi: 10.1016/j.jtcvs.2016.07.076

67. Frommelt PC, Frommelt MA, Tweddell JS, Jaquiss RD. Prospective echocardiographic diagnosis and surgical repair of anomalous origin of a coronary artery from the opposite sinus with an interarterial course. *J Am Coll Cardiol*. 2003;42:148–154. doi: 10.1016/S0735-1097(03)00503-5
68. Zeltser I, Cannon B, Silvana L, Fenrich A, George J, Schleifer J, Garcia M, Barnes A, Rivenes S, Patt H, et al. Lessons learned from preparticipation cardiovascular screening in a state funded program. *Am J Cardiol*. 2012;110:902–908. doi: 10.1016/j.amjcard.2012.05.018
69. Palmieri V, Gervasi S, Bianco M, Cogliani R, Poscolieri B, Cuccaro F, Marano R, Mazzari M, Basso C, Zeppilli P. Anomalous origin of coronary arteries from the "wrong" sinus in athletes: diagnosis and management strategies. *Int J Cardiol*. 2018;252:13–20. doi: 10.1016/j.ijcard.2017.10.117
70. Angelini P, Cheong BY, Lenge De Rosen VV, Lopez JA, Uribe C, Masso AH, Ali SW, Davis BR, Muthupillai R, Willerson JT. Magnetic resonance imaging-based screening study in a general population of adolescents. *J Am Coll Cardiol*. 2018;71:579–580. doi: 10.1016/j.jacc.2017.11.051
71. Angelini P, Cheong BY, Lenge De Rosen VV, Lopez A, Uribe C, Masso AH, Ali SW, Davis BR, Muthupillai R, Willerson JT. High-risk cardiovascular conditions in sports-related sudden death: prevalence in 5,169 schoolchildren screened via cardiac magnetic resonance. *Tex Heart Inst J*. 2018;45:205–213. doi: 10.14503/THIJ-18-6645
72. Brothers JA, McBride MG, Selim MA, Marino BS, Tomlinson RS, Pampaloni MH, Gaynor JW, Spray TL, Paridon SM. Evaluation of myocardial ischemia after surgical repair of anomalous aortic origin of a coronary artery in a series of pediatric patients. *J Am Coll Cardiol*. 2007;50:2078–2082. doi: 10.1016/j.jacc.2007.06.055
73. Bigler MR, Seiler C, Räber L, Gräni C. Wolf in sheep's clothing—The false sense of security in patients with anomalous aortic origin of a coronary artery undergoing submaximal stress testing. *J Invasive Cardiol*. 2021;33:E396–e397.
74. Ben-Dor I, Weissman G, Rogers T, Slack M, Pichard A, Ben-Dor N, Hashim H, Bernardo N, Satler LF, Waksman R. Catheter selection and angiographic views for anomalous coronary arteries. *J Am Coll Cardiol Interv*. 2021;14:995–1008. doi: 10.1016/j.jcin.2021.01.054
75. King NM, Tian DD, Munkholm-Larsen S, Buttar SN, Chow V, Yan T. The aberrant coronary artery—The management approach. *Heart Lung Circ*. 2018;27:702–707. doi: 10.1016/j.hlc.2017.06.719
76. Padalino MA, Jegatheeswaran A, Blitzer D, Ricciardi G, Guariento A. Surgery for anomalous aortic origin of coronary arteries: technical safeguards and pitfalls. *Front Cardiovasc Med*. 2021;8:626108.
77. Vinnakota A, Stewart RD, Najm H, Blackstone EH, Ghobrial J, Pettersson GB. Anomalous aortic origin of the coronary arteries: a novel unroofing technique in an adult cohort. *Ann Thorac Surg*. 2019;107:823–828. doi: 10.1016/j.athoracsur.2018.08.036
78. Mustafa I, Gula G, Radley-Smith R, Durrer S, Yacoub M. Anomalous origin of the left coronary artery from the anterior aortic sinus: a potential cause of sudden death. Anatomic characterization and surgical treatment. *J Thorac Cardiovasc Surg*. 1981;82:297–300. doi: 10.1016/S0022-5223(19)39371-7
79. Dekel H, Hickey EJ, Wallen J, Caldaroni CA. Repair of anomalous aortic origin of coronary arteries with combined unroofing and unroofing technique. *J Thorac Cardiovasc Surg*. 2015;150:422–424. doi: 10.1016/j.jtcvs.2015.05.013
80. Gaudin R, Raisy O and Vouhé PR. Anomalous aortic origin of coronary arteries: 'anatomical' surgical repair. *Multimed Man Cardiothorac Surg*. 2014;2014:mmt022. DOI: 10.1093/mmcts/mmt022.
81. Yerebakan C, Ozturk M, Mota L, Sinha L, Gordish-Dressman H, Jonas R, Sinha P. Complete unroofing of the intramural coronary artery for anomalous aortic origin of a coronary artery: the role of commissural resuspension? *J Thorac Cardiovasc Surg*. 2019;158:208–217.e2. doi: 10.1016/j.jtcvs.2019.01.140
82. Hatoum H, Krishnamurthy R, Parthasarathy J, Flemister DC, Krull CM, Walter BA, Mery CM, Molossi S, Dasi LP. Flow dynamics in anomalous aortic origin of a coronary artery in children: importance of the intramural segment. *Semin Thorac Cardiovasc Surg*. 2020;34:226–235. doi: 10.1053/j.semthor.2020.11.027
83. Romp RL, Herlong JR, Landolfo CK, Sanders SP, Miller CE, Ungerleider RM, Jagggers J. Outcome of unroofing procedure for repair of anomalous aortic origin of left or right coronary artery. *Ann Thorac Surg*. 2003;76:589–595; discussion 595-6.
84. Jagggers J, Lodge AJ. Surgical therapy for anomalous aortic origin of the coronary arteries. *Semin Thorac Cardiovasc Surg Pediatr Card Surg Annu*. 2005;8:122–127. doi: 10.1053/j.pcsu.2005.01.004:122-7
85. Cho SH, Joo HC, Yoo KJ, Youn YN. Anomalous origin of right coronary artery from left coronary sinus: surgical management and clinical result. *Thorac Cardiovasc Surg*. 2015;63:360–366. doi: 10.1055/s-0034-1376256
86. Razavi A, Sachdeva S, Frommelt PC, LaDisa JF Jr. Patient-specific numerical analysis of coronary flow in children with intramural anomalous aortic origin of coronary arteries. *Semin Thorac Cardiovasc Surg*. 2021;33:155–167. doi: 10.1053/j.semthor.2020.08.016
87. Erez E, Tam VK, Dublin NA, Stakes J. Anomalous coronary artery with aortic origin and course between the great arteries: improved diagnosis, anatomic findings, and surgical treatment. *Ann Thorac Surg*. 2006;82:973–977. doi: 10.1016/j.athoracsur.2006.04.089
88. van Son JA, Mohr FW. Modified unroofing procedure in anomalous aortic origin of left or right coronary artery. *Ann Thorac Surg*. 1997;64:568–569. doi: 10.1016/S0003-4975(97)00447-5
89. Herrmann JL, Goldberg LA, Khan AM, Partington SL, Brothers JA, Mascio CE, Spray TL, Kim YY, Fuller S. A comparison of perioperative management of anomalous aortic origin of a coronary artery between an adult and pediatric cardiac center. *World J Pediatr Congenit Heart Surg*. 2016;7:721–726. doi: 10.1177/2150135116668333
90. Law T, Dunne B, Stamp N, Ho KM, Andrews D. Surgical results and outcomes after reimplantation for the management of anomalous aortic origin of the right coronary artery. *Ann Thorac Surg*. 2016;102:192–198. doi: 10.1016/j.athoracsur.2016.02.002
91. Doan TT, Molossi S, Qureshi AM, McKenzie ED. Intraseptal anomalous coronary artery with myocardial infarction: novel surgical approach. *Ann Thorac Surg*. 2020;110:e271–e274. doi: 10.1016/j.athoracsur.2020.02.076
92. Doan TT, Zea-Vera R, Agrawal H, Mery CM, Masand P, Reaves-O'Neal DL, Noel CV, Qureshi AM, Sexson-Tejtel SK, Fraser CD, Jr., et al. Myocardial ischemia in children with anomalous aortic origin of a coronary artery with intraseptal course. *Circ Cardiovasc Interv*. 2020;13:e008375. doi: 10.1161/CIRCINTERVENTIONS.119.008375.
93. Najm HK, Karamlou T, Ahmad M, Hassan S, Salam Y, Majdalany D, Ghobrial J, Stewart RD, Unai S, Pettersson G. Early outcomes of transcatheter repair of transseptal anomalous left coronary artery from right sinus. *Ann Thorac Surg*. 2021;112:595–602. doi: 10.1016/j.athoracsur.2020.04.149
94. Izumi K, Wilbring M, Stumpf J, Matschke K, Kappert U. Direct reimplantation as an alternative approach for treatment of anomalous aortic origin of the right coronary artery. *Ann Thorac Surg*. 2014;98:740–742. doi: 10.1016/j.athoracsur.2013.12.075
95. Rogers SO Jr, Leacche M, Mihaljevic T, Rawn JD, Byrne JG. Surgery for anomalous origin of the right coronary artery from the left aortic sinus. *Ann Thorac Surg*. 2004;78:1829–1831. doi: 10.1016/S0003-4975(03)01501-7
96. Gaillard M, Pontallier M, Danial P, Moreau de Bellaing A, Gaudin R, du Puy-Montbrun L, Murtuza B, Haydar A, Malekzadeh-Milani S, Bonnet D, et al. Anomalous aortic origin of coronary arteries: an alternative to the unroofing strategy. *Eur J Cardiothorac Surg*. 2020;58:975–982.
97. Alphonso N, Anagnostopoulos PV, Nölke L, Moon-Grady A, Azakie A, Raff GW, Karl TR. Anomalous coronary artery from the wrong sinus of Valsalva: a physiologic repair strategy. *Ann Thorac Surg*. 2007;83:1472–1476. doi: 10.1016/j.athoracsur.2006.10.071
98. Vouhé PR. Anomalous aortic origin of a coronary artery is always a surgical disease. *Semin Thorac Cardiovasc Surg Pediatr Card Surg Annu*. 2016;19:25–29. doi: 10.1053/j.pcsu.2015.12.007
99. Imoto Y, Matsuba T, Kanda H, Ogata Y, Nagatomi S, Ueno K. Reimplantation of an anomalous left coronary artery with a malignant course. *Asian Cardiovasc Thorac Ann*. 2018;26:473–475. doi: 10.1177/0218492318782263
100. Cohen AJ, Grishkin BA, Helsel RA, Head HD. Surgical therapy in the management of coronary anomalies: emphasis on utility of internal mammary artery grafts. *Ann Thorac Surg*. 1989;47:630–637. doi: 10.1016/0003-4975(89)90454-2
101. Sabik JF III, Lytle BW, Blackstone EH, Khan M, Houghtaling PL, Cosgrove DM. Does competitive flow reduce internal thoracic artery graft patency? *Ann Thorac Surg*. 2003;76:1490–1496; discussion 1497. doi: 10.1016/S0003-4975(03)01022-1
102. Berger A, MacCarthy PA, Siebert U, Carlier S, Wijns W, Heyndrickx G, Bartunek J, Vanermen H, De Bruyne B. Long-term patency of internal

- mammary artery bypass grafts: relationship with preoperative severity of the native coronary artery stenosis. *Circulation*. 2004;110:li36–li40. doi: 10.1161/01.CIR.0000141256.05740.69
103. Fedoruk LM, Kern JA, Peeler BB, Kron IL. Anomalous origin of the right coronary artery: right internal thoracic artery to right coronary artery bypass is not the answer. *J Thorac Cardiovasc Surg*. 2007;133:456–460. doi: 10.1016/j.jtcvs.2006.10.011
 104. Tavaf-Motamen H, Bannister SP, Corcoran PC, Stewart RW, Mulligan CR, DeVries WC. Repair of anomalous origin of right coronary artery from the left sinus of Valsalva. *Ann Thorac Surg*. 2008;85:2135–2136. doi: 10.1016/j.athoracsur.2007.07.006
 105. Reul RM, Cooley DA, Hallman GL, Reul GJ. Surgical treatment of coronary artery anomalies: report of a 37 1/2-year experience at the Texas Heart Institute. *Tex Heart Inst J*. 2002;29:299–307.
 106. Moodie DS, Gill C, Loop FD, Sheldon WC. Anomalous left main coronary artery originating from the right sinus of Valsalva: pathophysiology, angiographic definition, and surgical approaches. *J Thorac Cardiovasc Surg*. 1980;80:198–205. doi: 10.1016/S0022-5223(19)37789-X
 107. Selig MB, Jafari N. Anomalous origin of the left main coronary artery from the right coronary artery ostium-interarterial subtype: angiographic definition and surgical treatment. *Catheter Cardiovasc Diagn*. 1994;31:41–47. doi: 10.1002/ccd.1810310110
 108. Khan MS, Idris O, Shah J, Sharma R, Singh H. Anomalous origin of left main coronary artery from the right sinus of Valsalva: a case series-based review. *Cureus*. 2020;12:e7777.
 109. Rodefeld MD, Culbertson CB, Rosenfeld HM, Hanley FL, Thompson LD. Pulmonary artery translocation: a surgical option for complex anomalous coronary artery anatomy. *Ann Thorac Surg*. 2001;72:2150–2152. doi: 10.1016/S0003-4975(01)03208-8
 110. Mainwaring RD, Hanley FL. Surgical treatment of anomalous left main coronary artery with an intraconal course. *Congenit Heart Dis*. 2019;14:504–510. doi: 10.1111/chd.12826
 111. Mainwaring RD, Reddy VM, Reinhartz O, Petrossian E, MacDonald M, Nasirov T, Miyake CY, Hanley FL. Anomalous aortic origin of a coronary artery: medium-term results after surgical repair in 50 patients. *Ann Thorac Surg*. 2011;92:691–697. doi: 10.1016/j.athoracsur.2011.03.127
 112. Guerra VC, Recto MR, Goldman C, Yeh T Jr. Anomalous aortic origin of the coronary artery: does pulmonary artery translocation affect coronary artery course? *J Thorac Cardiovasc Surg*. 2013;146:1549–1551. doi: 10.1016/j.jtcvs.2013.08.010
 113. Hariharan R, Kacere RD, Angelini P. Can stent-angioplasty be a valid alternative to surgery when revascularization is indicated for anomalous origination of a coronary artery from the opposite sinus? *Tex Heart Inst J*. 2002;29:308–313.
 114. Ceyhan C, Tekten T, Onbasili AO. Primary percutaneous coronary intervention of anomalous origin of right coronary artery above the left sinus of Valsalva in a case with acute myocardial infarction. Coronary anomalies and myocardial infarction. *Int J Cardiovasc Imaging*. 2004;20:293–297. doi: 10.1023/B:CAIM.0000041946.61659.a6
 115. Hershey J, Isada L, Fenster MS. Emergent primary PCI of anomalous LAD. *J Invasive Cardiol*. 2006;18:E152–E153.
 116. Doorey AJ, Pasquale MJ, Lally JF, Mintz GS, Marshall E, Ramos DA. Six-month success of intracoronary stenting for anomalous coronary arteries associated with myocardial ischemia. *Am J Cardiol*. 2000;86:580–582, a10.
 117. Aubry P, Halna du Fretay X, Boudvillain O, Degrell P. Place of angioplasty for coronary artery anomalies with interarterial course. *Front Cardiovasc Med*. 2020;7:596018. DOI: 10.3389/fcvm.2020.596018.
 118. Häner JD, Bär S, Ueki Y, Otsuka T, Gräni C, Räber L. Novel diagnostic approach to invasively confirm interarterial course of anomalous right coronary artery. *J Am Coll Cardiol Interv*. 2020;13:132–134. doi: 10.1016/j.jcin.2019.08.008
 119. de Agustín JA, Marcos-Alberca P, Manzano Mdel C, Fernández-Golfín C, Pérez de Isla L, Hernández-Antolín R, Macaya C, Zamorano J. Percutaneous Intervention in a single coronary artery: evaluation of multislice tomography and its feasibility. *Rev Esp Cardiol*. 2010;63:607–611. doi: 10.1016/S0300-8932(10)70124-X
 120. Unzué L, García E, López-Melgar B, Agudo-Quilez P. Percutaneous treatment of an anomalous left main arising from the opposite sinus with subpulmonic course. *Cardiovasc Revasc Med*. 2018;19:632–637. doi: 10.1016/j.carrev.2018.01.008
 121. Bixby MB. Successful medical management of a patient with an anomalous right coronary artery who declined surgery. *Am J Crit Care*. 1998;7:393–394. doi: 10.4037/ajcc1998.7.5.393
 122. Barbou F, Schiano P, Lahutte M. Anomalous right coronary artery from the left coronary sinus, with an interarterial course. *Arch Cardiovasc Dis*. 2010;103:626–628. doi: 10.1016/j.acvd.2010.01.010
 123. Wen CP, Wai JP, Tsai MK, Yang YC, Cheng TY, Lee MC, Chan HT, Tsao CK, Tsai SP, Wu X. Minimum amount of physical activity for reduced mortality and extended life expectancy: a prospective cohort study. *Lancet (London, England)*. 2011;378:1244–1253. doi: 10.1016/S0140-6736(11)60749-6
 124. Steptoe A, Butler N. Sports participation and emotional wellbeing in adolescents. *Lancet (London, England)*. 1996;347:1789–1792. doi: 10.1016/S0140-6736(96)91616-5
 125. Angelini P, Walmsley R, Cheong BY, Ott DA. Left main coronary artery originating from the proper sinus but with acute angulation and an intramural course, leading to critical stenosis. *Tex Heart Inst J*. 2010;37:221–225.
 126. Neumann F-J, Sousa-Uva M, Ahlsson A, Alfonso F, Banning AP, Benedetto U, Byrne RA, Collet J-P, Falk V, Head SJ, et al. 2018 ESC/EACTS guidelines on myocardial revascularization. *Eur Heart J*. 2018;40:87–165.
 127. Fihn SD, Gardin JM, Abrams J, Berra K, Blankenship JC, Dallas AP, Douglas PS, Foody JM, Gerber TC, Hinderliter AL, et al. 2012 ACCF/AHA/ACP/AATS/PCNA/SCAI/STS guideline for the diagnosis and management of patients with stable ischemic heart disease. *Circulation*. 2012;126:e354–e471. doi: 10.1161/CIR.Ob013e318277d6a0
 128. Brothers JA, Gaynor JW, Jacobs JP, Caldaroni C, Jegatheeswaran A, Jacobs ML. The registry of anomalous aortic origin of the coronary artery of the Congenital Heart Surgeons' Society. *Cardiol Young*. 2010;20:50–58. doi: 10.1017/S1047951110001095
 129. Padalino MA, Franchetti N, Sarris GE, Hazekamp M, Carrel T, Frigiola A, Horer J, Roussin R, Cleuziou J, Meyns B, et al. Anomalous aortic origin of coronary arteries: Early results on clinical management from an international multicenter study. *Int J Cardiol*. 2019;291:189–193. doi: 10.1016/j.ijcard.2019.02.007